

Case study

Migrated feeding tube; a rare complication of distal feeding enteroclysis

Abstract:

In emergency, often a proximal stoma is created in view of compromised general condition of the patient (severe sepsis, nutritional compromise, low albumin, vasopressor supports, multiorgan dysfunction) while operating for intestinal obstruction, perforation, bleeding or ischemia etc. Proximal stoma results in high output and consequent fluid and electrolyte deficit. Refeeding or enteroclysis of succus entericus into the distal mucous fistula is a well-known strategy for such patients. It reduces dependence on parenteral nutrition and facilitates faster transition to acceptable and sustainable home based therapy till the restoration of bowel continuity. Although this is an effective and safe procedure, certain known complications like non-tolerance to the refeed, bowel perforation, diarrhoea, and peristomal skin excoriation have been reported. Migration of entire Foley's catheter used for distal refeed, getting entrapped at IC junction is a rare complication, not reported till date. We, present a case of 59-years gentleman of abdominal tuberculosis, who presented with lower GI bleeding. He underwent laparotomy and diagnostic enteroscopy and ended-up having a proximal stoma. He received ATT post-operatively and distal refeeding through a Foley's catheter. After 1.5 months, he presented with migration of feeding catheter. Endoscopic retrieval was unsuccessful. Thus, exploratory laparotomy and retrieval of feeding catheter was done. This was a rare complication in usual surgical practice which could have prevented with proper patient counselling.

Key Words: Abdominal tuberculosis, Lower gastrointestinal bleeding, Intra-op enteroscopy, proximal stoma, distal refeeding, migration of Foleys catheter, surgical retrieval

Introduction:

In emergency settings, we face many situations where proximal bowel enterotomy or resection is required but condition of the patient (severe sepsis, nutritional compromise, low albumin, vasopressor supports, multiorgan dysfunction) does not permit the restoration of the bowel continuity in the same setting. Consequently, this leaves the patient with a very proximal stoma and insufficient bowel length to maintain adequate nutrition, added by high stoma output leading to fluid-electrolyte imbalance and protein loss. Refeedingenteroclysis, or refeeding of succus entericus into the distal mucous fistula is a well-known strategy opted in such patients. It reduces dependence on parenteral nutrition and facilitate faster transition to acceptable and sustainable home based therapy till the restoration of bawel continuity is achieved again. This allows distal bowel to be utilized to allow normal digestion and absorption of fluid-electrolytes and nutrients, at the same time prevents atrophy of the distal gastrointestinal tract [1].

Although this is an effective and safe procedure, certain known complications have been described like non-tolerance to the refeed, bowel perforation, diarrhea, and peristoma skin excoriation. We faced a unique problem of migration of entire Foley's catheter used for distal reefed, getting entrapped at IC junction and reporting the same in a patient who presented with overt gastrointestinal (GI) bleed in the background of diffuse abdominal tuberculosis and required the formation of a proximal stoma and distal refeedingenteroclysis.

Case Report:

A 59-year old gentleman presented to the emergency with overt GI Bleed in the form of persistent **melenaand anemia**. Hemoglobin was **found to be 4 gm%**, rest all parameters were within normal limits. Upper GI endoscopy showed normal study. Colonoscopy also showed presence of blood in caecum and terminal ileum and also revealed multiple non-bleeding ulcers in the transverse colon. **Triple phase computed tomogram (CT) showed an active blush in proximal jejunal loops** (Figure 1)

bercular abdomen - multiple focal hypodense nodular lesions in the subcapsular region of the liver with overlying thickened capsule giving the classical description of "sugar coating of liver" or 'frosted liver'(Figure 2), multiple mesenteric nodes, diffuse fat and omental

stranding, and a necrotic cavity extending from the base of sigmoid colon upto hepatic flexure.

Antitubercular treatment (ATT) was started and blood products were transfused. Bleeding persisted, however; there was continual drop in haemoglobin. Hence, patient was taken up for emergency laparotomy and diagnostic enteroscopy. Intraoperatively, there were dense inter-bowel and bowel to parietal wall adhesions present. After adhesiolysis, an enterotomy was made **inmid smallbowel for enteroscopy**.

Entire small bowel was evaluated and it demonstrated blood in **the small bowel without any active bleeding site**. Few necrotic lymph nodes were sampled for the biopsy. In view of poor general condition, friable bowel, and possibility of recurrent bleeding, the site of **enterotomy was brought out as a loop stoma**.

Histopathology was consistent with the diagnosis of tuberculosis. Fortunately, in the post-operative period patient did not have any further bleed episode. He had persistently high output from the stoma and consequent malnutrition and electrolyte imbalance. This necessitated the distal bowel refeed of proximal stoma effluents after entubating the distal limb of stoma with a Foley's catheter (FC). Patient tolerated the refeed and recovered well on ATT and was discharged to home.

After 1.5 month, he presented with **migration of FC into** the distal bowel with dehydration and acute kidney injury (AKI). He was resuscitated and abdominal sonography showed a migrated FC in the small bowel. Computed tomography (CT) imaging was performed after correction of AKI which revealed **the entire FC with a 2 ml syringe with plunger (at the proximal end of catheter) stuck at the ileo-caecal junction (ICJ)** (distal part in right colon with bulb inflated and proximal part with syringe plunger in distal ileum) (Figure 3).

Initially, retrieval of Foleys bulb was attempted with colonoscopy, where the bulb of the Foley's catheter was punctured but it was stuck at the ICJ. Distal bowel enteroscopy was performed, however; it couldn't be removed as the hard plunger of the syringe was difficult to catch and was lying in such an alignment that even after catching it could not be dragged out of bowel (Figure 4). Patient was taken up for surgery, stoma was mobilised and bowel was distally traced. **Fortunately, because of ATT, this time adhesions were minimal and the bowel**

also became soft and supple. After palpating the foley's catheter, an enterotomy was made in the small bowel and catheter was retrieved(Figure 5). Both the enterotomy and stoma were closed. Post-operative period was uneventful and discharged on day-7 with ATT. He is asymptomatic till date (12 months follow-up) and has completed ATT.

Discussion:

Distal stoma refeeding or enteroclysis, is an established method of utilizing the distal bowel, and it works as an effective nutritional therapy for patients with functional short bowel syndrome due to proximal stoma but with distal viable sufficient bowel length, acting as a bridge to definitive surgery [2]. It helps to reduce the parenteral nutrition related cost and complications.

Distal stoma refeed is done through the distal mucus fistula with soft catheter. Most commonly used is a Foley's catheter for this purpose. Numerous complications have been reported, like non-tolerance of feed, peri-stoma skin excoriation, bowel perforation due to the catheter etc. anecdotal case reports of migration of feeding gastrostomy tube have been published[3-5], however; migration of distal refeeding catheter with attached syringe and plunger has not been reported. This can occur because of pro-grade peristalsis of the bowel, pulling the catheter inside the bowel as in our case especially in post discharge nonhospital unsupervised settings. This can lead to an unwarranted emergency situation with obstruction or perforation. The clinician should be vigilant about this condition and patient should also be cautioned about the same. This catheter should be fixed at the abdominal wall, not allowing any migration in the bowel.

There are no definite protocols or guidelines as to the management of GI foreign bodies. Most of the described management strategies are anecdotal. Mostly if foreign bodies make it beyond the ICJ, they pass per rectally. Almost 80-90% foreign bodies pass through the GI tract unaided[5]. The physical characteristics of the object, whether blunt or sharp also guide the urgency, waiting period and therapeutic intervention. Indications for intervention either include acute abdomen secondary to impaction and consequent ischemia or obstruction and non-progression for periods greater than a week in non-sharp objects[6,7].

This report brings into the light the disadvantage of using Foleys catheter as a means of feeding as these are prone for antegrade migration due to the inflatable bulb at the tip and

lacks of an external anchoring system. Hence utmost care is needed on the part of caregivers to prevent migration due to forward bowel peristalsis and consequent disastrous complications such as obstruction, ischemia, perforation, ulceration, and intussusception. Wearable refeeding pumps are still in the initial stages of development [8,9]. At present no ideal catheter or tube has been designed or is available for refeeding enteroclysis through a mucus fistula. So whichever tube is used, it is absolutely necessary to fix it to the stoma bag or adjacent skin to prevent dislodgement.

Conclusion:

Distal stoma refeed is an established and safe way of maintaining the nutrition. Migration of catheter used for the refeed is possible due to prograde peristalsis and the clinician should be vigilant. These catheters should be anchored to the abdominal wall and the patient should be cautioned about the possibility of catheter migration. This case was unique in a way of rare imaging findings of a “frosted liver” in abdominal tuberculosis, and migration of Foleys catheter into the distal ileum, presenting with acute abdomen and subsequent management.

References

1. Sricharan, R., Chawla, A., Kumar, S. et al. Reinfusion Enteroclysis Can Successfully Replace Parenteral Feeding in Patients with High-Output Enteral Fistula or Ostomy Awaiting Definitive Surgery. *Indian J Surg* 82, 848–854 (2020). <https://doi.org/10.1007/s12262-020-02118-w>
2. Klek S, Forbes A, Gabe S, et al. Management of acute intestinal failure: A position paper from the European Society for Clinical Nutrition and Metabolism (ESPEN) Special Interest Group. *Clin Nutr.* 2016;35(6):1209-1218. doi:10.1016/j.clnu.2016.04.009
3. Lenzen H, Weismüller T, Bredt M, Bahr M. Education and imaging. Gastrointestinal: PEG feeding tube migration into the colon; a late manifestation. *J Gastroenterol Hepatol.* 2012;27(7):1254. doi:10.1111/j.1440-1746.2012.07157.x

4. Sbeit, W., Assy, N., Kadah, A. et al. (2017). Foley Catheter Gastric Tube Feeding Migration as a Cause of Acute Pancreatitis. *JOP. J Pancreas (Online)*, 18(2), 170-174. [JOP. Journal of the Pancreas - <http://pancreas.imedpub.com/> - Vol. 18 No. 2 – Mar 2017. [ISSN 1590-8577]
5. Cmorej P, Barbat S, Sugawa C. Complication of dislodged gastrostomy Foley catheter: antegrade migration into small bowel. *BMJ Case Rep.* 2018;11(1):e227551. Published 2018 Dec 18. doi:10.1136/bcr-2018-227551
6. Smith MT, Wong RK. Foreign bodies. *GastrointestEndoscClin N Am.* 2007;17(2):361-vii. doi:10.1016/j.giec.2007.03.002
7. ASGE Standards of Practice Committee, Ikenberry SO, Jue TL, et al. Management of ingested foreign bodies and food impactions. *GastrointestEndosc.* 2011;73(6):1085-1091. doi:10.1016/j.gie.2010.11.010
8. Levy E, Cosnes J, Parc R, Bloch P, Huguet C, Loygue J. Réinstillation continue du chyme en réanimation digestive: mise en évidence d'une rétro-action négative sur le débit sécrétoire digestif [Continuous reinstallation of chyme in digestive resuscitation: demonstration of negative retro-action on the digestive secretion output]. *Nouv Presse Med.* 1979;8(10):782-783.
9. Levy E, Frileux P, Sandrucci S, et al. Continuous enteral nutrition during the early adaptive stage of the short bowel syndrome. *Br J Surg.* 1988;75(6):549-553. doi:10.1002/bjs.1800750615

Figure legends:

Figure 1:Picture A shows blush in proximal jejunal loop as indicated by the arrow. Picture B Reveals multiple mesenteric nodes with diffuse fat and omental stranding .C-D show the necrotic cavity extending from base of sigmoid colon up to the hepatic flexure.

Figure 2: “Frosted appearance of liver” with multiple subcapsular hypodense lesions as indicated by arrows

Figure 3: CECT picture (A and B) showing Inflated Foley’s Bulb. C and D showing the plunger of the syringe

Figure 4: Endoscopic pictures(A-D) showing the entrapped foleys at IC junction .Snare being used to attempt retrieval of foley’s catheter.

Figure 5: Surgical removal of feeding catheter (An enterotomy was made and catheter gently manipulated and pulled out . Enterotomy site and ileostomy closure was done subsequently.)

Figure 1:

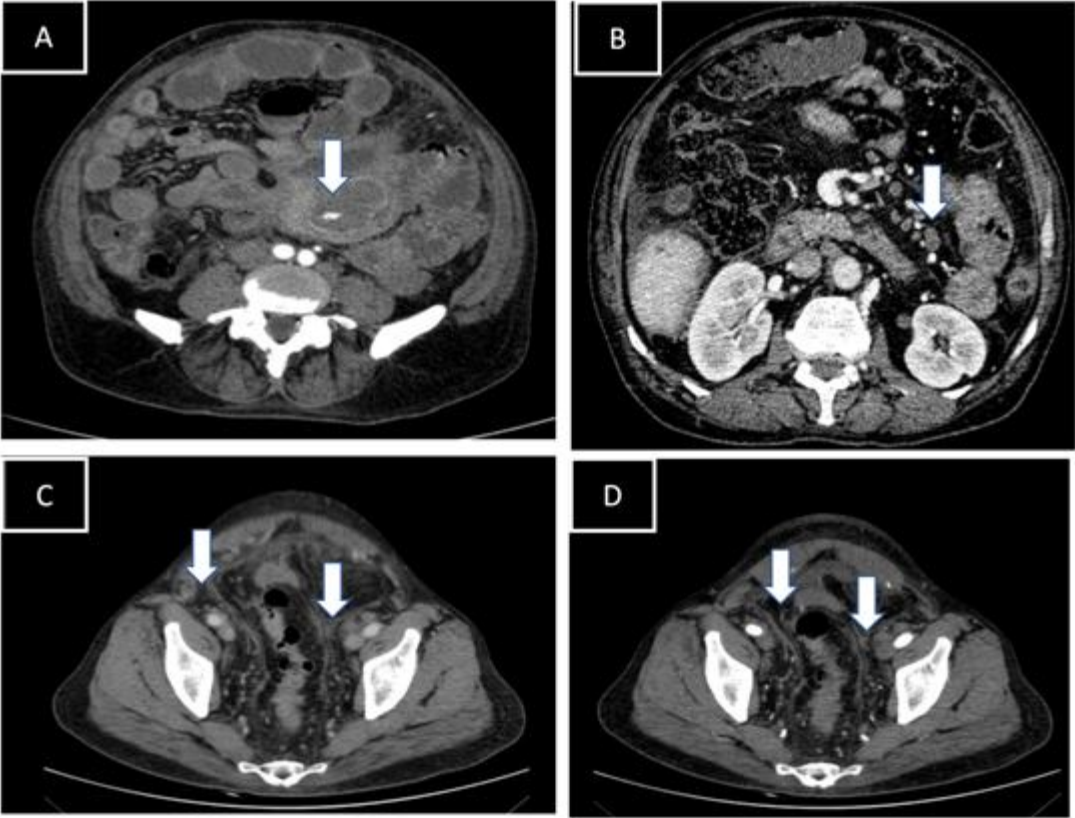


Figure 2:

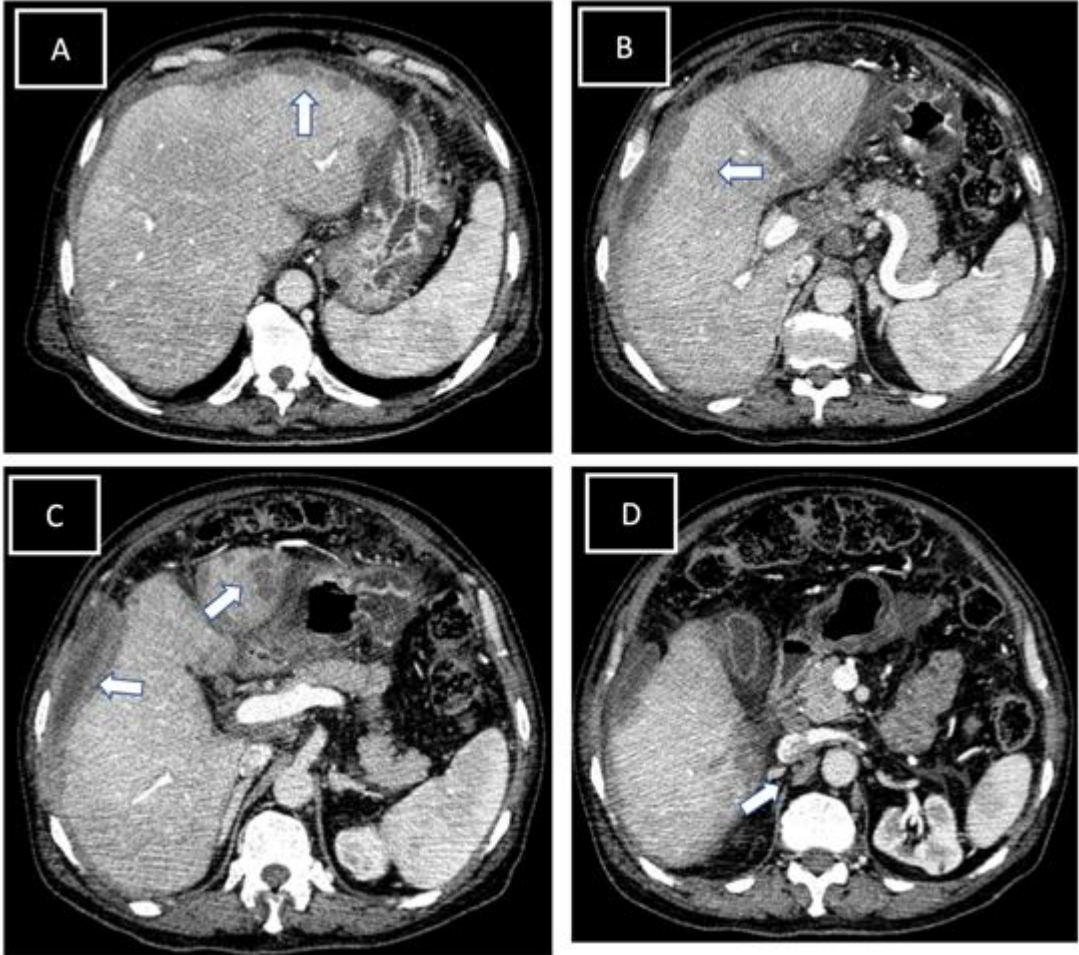


Figure 3:

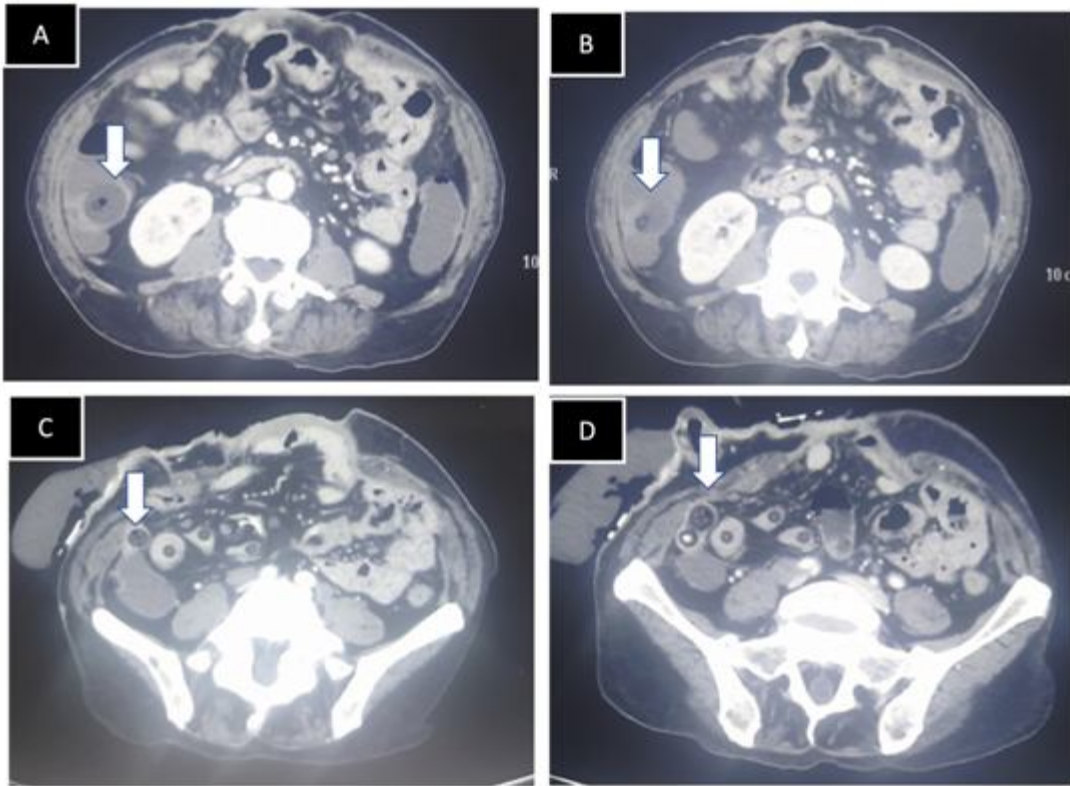


Figure 4:

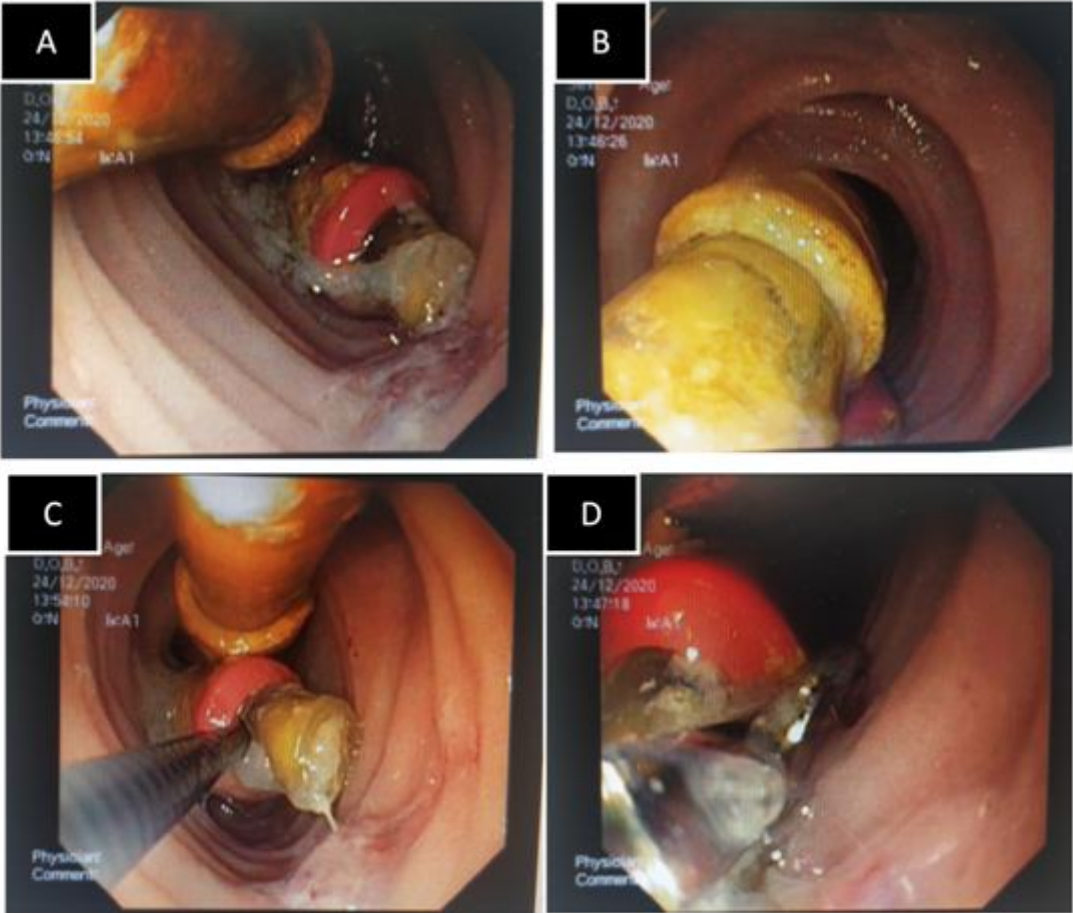


Figure 5:

