

# **SOME FEATURES OF THE CLINICAL COURSE OF PARASAGITTAL MENINGIOMAS OF THE BRAIN**

## **Abstract**

Brain tumors account for 6-8% of all types of neoplasms. Of these, meningiomas occur in 27.9% of patients, of which 20% among men and 33.2% among women. According to various authors, brain tumors develop annually in 2-25 per 100,000 population. The connection between traumatic brain injury and the development of shell-vascular tumors has been proven. The dependence of the frequency of occurrence of brain tumors on age was revealed. So, up to the age of 7, brain tumors are more common than from 7 to 14 years, and from the age of 14, the frequency of tumors increases again, reaching a maximum by the age of 50, after which it decreases again. In the course of the study, we studied the clinical features of the course of parasagittal meningiomas.

**Keywords:** parasagittal meningiomas, symptoms, tractography

## **Introduction**

Meningiomas of the cerebral hemispheres account for approximately 47% of all supratentorial meningiomas. Among them, the incidence of parasagittal meningiomas ranges from 20.5 to 40.0%, which makes up a significant part of neuro-oncological patients.

Despite the development of modern diagnostics, the diagnosis of brain meningioma remains difficult and unsystematic. Currently, new medical equipment and various methods of laboratory diagnostics have appeared in Uzbekistan. These equipment can improve the diagnosis and, in turn, the results of treatment, but still early diagnosis of meningioma remains problematic. Thus, to further improve the diagnosis and comprehensive treatment of parasagittal meningiomas of the brain, new scientific research and new medical equipment such as MR tractography, Fiber tractography, MR spectroscopy, MR angiography are required.

It is extremely important to determine the tactics of meningioma treatment is timely recognition and obtaining the most complete information about its localization and size, sources of blood supply.

**The purpose of the research:** to study of clinical features of the course of parasagittal meningiomas of the brain

**Case Presentation:** We observed 72 patients with meningiomas of the cerebral hemispheres who were treated in the neurosurgical department of the clinic of the Samarkand State Medical University in the period from 2016 to 2021, of which 38 patients were under their own supervision and 34 - an analysis of materials on archival medical histories was carried out. 80% of the patients were subjected to surgical intervention.

When distributing patients with brain tumors of the large hemispheres by age, we used the generally accepted WHO classification. The age of patients ranges from 20 years to 66 years, the average was  $35.7 \pm 13.9$  years. By age, all patients with meningiomas of the cerebral hemispheres are divided into 3 groups.

Parasagittal meningiomas of the brain were more often detected in patients aged 19 to 45 years, which accounted for 61.3%. It was followed by patients aged 46 to 64 years – 24%, and patients aged 4 to 18 years made up 14.7%.

Patients by gender were distributed as follows: men were 50.7%, and women– 49.3%, i.e. there is an equal frequency of occurrence of parasagittal meningiomas of the brain in both sexes. The presence of parasagittal meningioma of various localization was also determined (Table 1).

**Table 1**

**Distribution of patients by localization**

<b>Localization of meningiomas</b>	<b>n</b>
Anterior third of the sagittal sinus and olfactory fossa	24 (33,3%)
The middle third of the sagittal sinus	27 (37,5%)
Posterior third of the sagittal sinus	18 (25,0%)
Wing of the main bone	3 (4,1%)

**Discussion:** In the course of our study, we found that of the general cerebral symptoms, headaches, dizziness and vomiting were among the early symptoms of the disease, which more often had a paroxysmal character, became constant in a short period of time and increased in intensity.

One of the early symptoms of meningiomas of the brain is headache, which occurs in 65 (90.2%) patients. It occurred against the background of intracranial hypertension and irritation of the dura mater.

Dizziness and tinnitus in meningiomas were presented by 47.2% and 48.6% of patients. They manifested themselves against the background of a constant and paroxysmal headache.

Nausea and vomiting were observed in 79.1% and 59.7% of patients with meningiomas of the cerebral hemispheres. Vomiting had specific signs, namely, it occurred regardless of the meal, sometimes in the morning.

Mental disorders occurred in 33.3% of patients and manifested apathy in 24.4%, lack of initiative in 17.8%, decreased memory and intelligence in 52.7%, as well as aggressiveness in 5.1%. This was especially clearly noted when tumors were localized in the frontal lobes - 42%, often in the parietal and temporal lobes - 23%. Mental disorders developed gradually with other general cerebral symptoms as a result of an increase in the phenomenon of intracranial hypertension, edema and hypoxia of the brain.

Paresis in the extremities was observed in 40 (55.5%) patients who had hemiparesis on the right in 17 (23.6%), hemiparesis on the left in 19 (26.3%), monoparesis 3 (4.1%) and tetraparesis (1.4%) (Table 2).

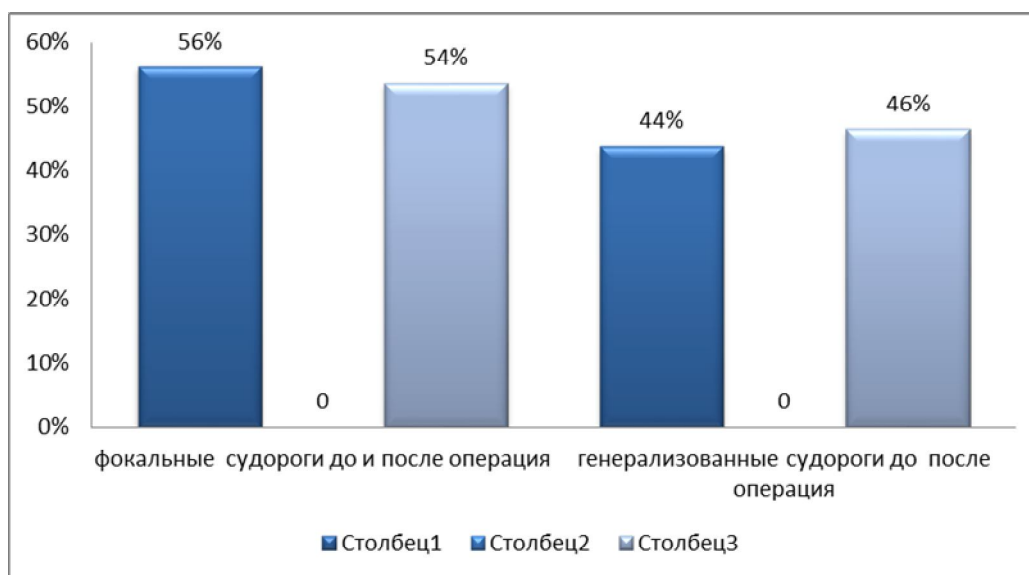
**Table 2**

**Frequency of occurrence of neurological symptoms in patients diagnosed with meningioma of the brain before and after surgery**

Neurological syndromes	Before the operation		After surgery, on the day of discharge	
	n	%	n	%
Headache	65	90,2 %	23	31,9%

Dizziness	34	47,2%	12	16,6%
Stagnation of the fundus	18	25%	6	8,2%
Hemiparesis and hemiplegia	40	55,5%	37	51,3%
Tinnitus	35	48,6%	7	9,7%
Nausea	57	79,1%	13	18%
Vomiting	43	59,7%	9	12,5%
Episindrome	48	66,6%	41	56,9%
Mental disorders	24	33,3%	6	8,3%
Sensitivity disorders	15	20,8 %	19	26,3%

Epileptic seizures have a certain significance in meningiomas of the brain. In our observations in the preoperative period, epileptic syndrome was observed in 48 (66, %) patients out of 72 patients. Of these, focal seizures were noted in 27 (56.2%) cases, and generalized seizures occurred in 21 (43.8%) patients, and epileptic syndrome in 41 (56.9) patients after surgery on the day of discharge. Of these, 22 (53.6%) had focal seizures, and 19 (46.4%) patients had generalized seizures (Fig. 1).



**Fig. 1. Frequency of focal and generalized seizures before and after surgery**

Tumors in patients with epileptic seizures were mainly localized in the parietal lobe 22 (45.8%) and with tumors of the frontal lobe and in the anterior third of the

sagittal sinus, epipripadas were observed in 13 (27.0%) patients, of which the temporal lobe 9 (18.7%), and in 4 (8.3%) patients in other lobes.

With the help of MRI, the size of the tumor was reliably determined and whether or not there was a displacement of the median structures, as well as the presence of perifocal edema.

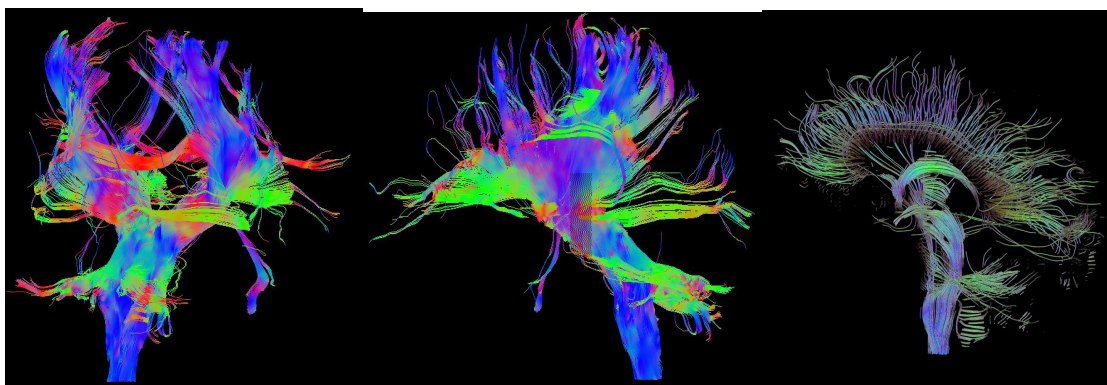
**Table 3**

**The ratio of tumor sizes, displacement of median structures and perifocal edema**

<b>Tumor size</b>	<b>number of patients</b>	<b>Displacement of median structures</b>	<b>Presence of perifocal edema</b>
Up to 1.0x0.5x1.0cm	5 (6,9%)	Not observed	Not observed
Up to 3.0x2.5x3.0cm	16 (22,2%)	Not observed	4 (5,5%)
Up to 5.0x4.5x5.0cm	19 (26,3%)	11 (15,2%)	16 (22,2%)
Up to 7.0x6.5x7.0cm	17 (23,6%)	15 (20,8%)	13 (18%)
> 7.0x6.5x7.0cm	15 (20,8%)	14 (19,4%)	15 (20,8%)

As Table 3 shows, only 5 patients applied to the neurosurgery clinic with small meningioma sizes (up to 1 cm). The majority of patients (about 71%) had large tumors (from 5.0x4.5x5.0cm to 7.0x6.5x7.0cm or more), 55.5% of patients had a mixture of median brain structures, displacements ranged from 5 mm to 8mm or more. Perifocal edema was observed in 66.6% of patients.

When planning surgical access to meningiomas, 4 patients underwent MR-tractography (Fig. 2).



## Fig. 2. Diffusion tensor visualization (DTV, DTI), or MR tractography

As can be seen on this tractography, a complete break of the corticospinal tract is noted at the level of the location of the meningioma. The patient has left-sided hemiparesis, impaired functions of the facial, olfactory, oculomotor nerves, mental disorders and epileptic seizures.

**Conclusions:** Thus, it can be concluded that the determination of the above patterns of clinical course helps to diagnose early complications and perform timely surgical treatment.

### References:

1. Ravshanov, D. M. (2022). Frequency and peculiarities of localisation of parasagittal meningiomas of the cerebral hemispheres. *International Journal of Health Sciences*, 6(S2), 6035–6041. <https://doi.org/10.53730/ijhs.v6nS2.6566>
2. Hua, L., Wang, D., Zhu, H., Deng, J., Luan, S., Chen, H., ... & Gong, Y. (2020). Long-term outcomes of multimodality management for parasagittal meningiomas. *Journal of Neuro-Oncology*, 147(2), 441-450.
3. David, D. S. (2019). Parasagittal meningioma brain tumor classification system based on MRI images and multi phase level set formulation. *Biomedical and Pharmacology Journal*, 12(2), 939-946.
4. Cai, Q., Wang, S., Wang, J., Tian, Q., Huang, T., Qin, H., & Feng, D. (2021). Classification of Peritumoral Veins in Convexity and Parasagittal Meningiomas and Its Significance in Preventing Cerebral Venous Infarction. *World Neurosurgery*, 149, e261-e268.
5. Sh, S. A., & Ravshanov, D. M. (2022). DETERMINATION OF THE EFFICACY OF THE USE OF NOOTROPES IN THE TREATMENT OF BRAIN CONCUSSION IN THE ACUTE PERIOD. *Web of Scientist: International Scientific Research Journal*, 3(6), 515-519.
6. Balik, V., Kourilova, P., Sulla, I., Vrbkova, J., Srovnal, J., Hajduch, M., & Takizawa, K. (2020). Recurrence of surgically treated parasagittal meningiomas: a meta-analysis of risk factors. *Acta Neurochirurgica*, 162(9), 2165-2176.

7. Eichberg, D. G., Casabella, A. M., Menaker, S. A., Shah, A. H., & Komotar, R. J. (2020). Parasagittal and parafalcine meningiomas: integral strategy for optimizing safety and retrospective review of a single surgeon series. *British journal of neurosurgery*, 34(5), 559-564.

8. Martinez-Perez, R., Hardesty, D. A., Palmer, J., Zachariah, M., Otto, B. A., Carrau, R. L., & Prevedello, D. M. (2020). Remote leptomeningeal dissemination in olfactory neuroblastoma mimicking multiple parasagittal meningiomas: diagnostic and therapeutic challenge. *World neurosurgery*, 134, 361-364.