

## **Original Research Article**

The efficacy of ultrasound guided platelet rich plasma injection versus perineural dextrose injection in the treatment of severe carpal tunnel syndrome

### **ABSTRACT**

**Aims:** to compare the ultrasound-guided platelet rich plasma efficacy to ultrasound guided 5% dextrose perineural injection therapy in severe idiopathic carpal tunnel syndrome patients.

**Patients and Methods:** This research involved 60 patients with severe idiopathic CTS diagnosed by electrophysiological study. Patients were evaluated at three months after injection clinically, electrophysiological, and US examinations.

**Patients were divided into 2 groups according to line of treatment:**

**Group I:** 30 patients (34 hands) treated by two ultrasound guided injection with 3 mL PRP two weeks apart.

**Group II:** 30 patients (35 hands) treated by two ultrasound guided perineural injection therapy with 3 ml of 5% dextrose two weeks apart.

**Results:** There was significant clinical improvement (BCTQ and, VAS), electrophysiological improvement (DML, AMP, sensory amplitude and sensory conduction velocity of median nerve) and, ultrasonic improvement (CSA and FR) 3 month after treatment as compared to before treatment in both groups with better improvement in group 1.

There was significant difference between the 2 groups regarding VAS for pain and VAS for paresthesia 3 months after treatment with better improvement in PRP group. There was significant difference between the 2 groups regarding BCTQ 3 months after treatment with better improvement in PRP group.

**Conclusion:** - Ultrasound guided injection of PRP or dextrose 5% is an effective and safe treatment for severe idiopathic CTS.

-Both modalities lead to significant reduction in pain, paresthesia, disability and also significant improvement in electrophysiological and ultrasound parameters of the median nerve with better improvement in PRP group.

**Key words:** Carpal tunnel syndrome, Ultrasound guided platelet rich plasma injection, Perineural dextrose injection,

## INTRODUCTION

Carpal tunnel syndrome (CTS) is one of the most distressing upper limb entrapment neuropathies.<sup>(1)</sup> It is a medical disorder caused by compression of the median nerve within the carpal tunnel as it travels through the wrist. The most common cause for CTS is idiopathic or secondary to other medical condition as diabetes mellitus, hypothyroidism, and wrist fracture.<sup>(2)</sup>

CTS is the most prevalent nerve compression syndrome, affecting an estimated one in ten persons over their lifetime.<sup>(3)</sup> Between the ages of 45 and 60, women are three times as likely as males to suffer from CTS.<sup>(4)</sup> Pain, numbness, and tingling in the thumb, index finger, middle finger, and radial side of the ring finger are the primary symptoms of CTS. Symptoms often begin gradually, become worse over the night, and may extend up to the arm; upon awakening, the patient typically finds comfort by shaking or massaging his or her hands. In severe situations, degeneration of the thenar muscles may result in a weakened hand grasp. In over fifty percent of cases, both parties are affected. This can result in considerable activity limitation, occupational impairment, and pain.<sup>(5)</sup>

Diagnosis is usually based on clinical history taking, examination and is supported by nerve conduction studies (NCS).<sup>(6,7)</sup> In recent years, ultrasonography (US) has shown ability to detect the median nerve compression and exclude space occupying lesions and, has been used in guided injections for the treatment of several conditions.<sup>(8)</sup>

The general therapy is often classified into two categories: conservative treatment and surgical release of the median nerve. Surgical treatment is typically reserved for the most severe manifestations of a disease. Treatments should be as conservative as possible, especially for mild and moderate types.<sup>(9)</sup> These treatments include local injections, physical modalities and medications.<sup>(10)</sup>

Platelet-rich plasma (PRP) contains concentrated platelets and several growth factors that stimulate wound healing/growth, angiogenesis, and axon regeneration. Since the 1980s, PRP has been widely used in dentistry, orthopedics, ophthalmology, neurosurgery, and cosmetic surgery as a safe and innovative treatment.<sup>(11)</sup> Moreover, PRP has an anti-inflammatory effect, which could contribute to early pain relief.<sup>(12)</sup>

Perineural injection therapy is a technique involves the injection of dextrose solution near the peripheral nerve and has been found to provide promising pain-relief benefits.<sup>(13)</sup> Notably, 5% dextrose has an osmolality similar to that of normal saline, and on injection is less painful than sterilized water.<sup>(14)</sup>

## Patients and Method

This study included 60 patients with severe idiopathic CTS diagnosed by electrophysiological study (classified according to Padua L, et al, neurophysiological classification of CTS)<sup>(15)</sup>. They were selected from the outpatient clinic of Physical Medicine, Rheumatology & Rehabilitation Department, Tanta University Hospitals.

### **Exclusion criteria:**

Diabetes mellitus, Thyroid diseases and other endocrinal diseases, Cervical radiculopathy, polyneuropathy and brachial plexopathy, Renal & hepatic diseases, Previous traumatic median nerve injury, wrist trauma, fracture, Pregnancy, Space occupying lesions in the tunnel as ganglia, neural tumour and tenosynovitis excluded by musculoskeletal ultrasound, Connective tissue diseases and rheumatoid arthritis, Medications as contraceptive pills and corticosteroids, Previous local injection treatment for carpal tunnel syndrome in the past 6 months, Bleeding disorders or receiving anticoagulant, Bifid median nerve determined on US examination, Previous carpal tunnel release surgery.

Every patient was injected with ultrasound guidance and, under aseptic technique. Sterilization was done using 70% alcohol-based solution (ethanol) by wiping the area of injection site.

### **Patients were divided into two groups:**

- **Group 1 (local injection by PRP):** 30 patients with idiopathic severe CTS. They received two injection (two weeks apart) with 3 mL PRP (2-ml of PRP were used to remove the nerve from the flexor retinaculum via hydrodissection, and a residual 1-ml was injected to the inferior part of the median nerve to separate it from the underlying subsynovial connective tissue and flexor tendons).
- **Group 2 (local injection by D5W):** 30 patients with idiopathic severe CTS. They received two Perineural injection (two weeks apart) therapy with 3 ml of 5% dextrose 2-ml of 5% dextrose were used to remove the nerve from the flexor retinaculum via hydrodissection, and a residual 1-ml was injected to the inferior part of the median nerve to separate it from the underlying subsynovial connective tissue and flexor tendons.

All patients were instructed to stop any anti-inflammatory medications except acetaminophen and, any other management approaches for CTS, for 2 weeks before and throughout the study period. Musculoskeletal ultrasound was done for all patients to determine CSA, FR and, exclude any space occupying lesion or any anatomical variations of the median nerve.

❖ **All patients were subjected to detailed history and complete clinical examination:**

**History:**

- Personal History
- History of present illness

**Examination:**

**1-neurological examination**

**2-Provocative tests for entrapment of the median nerve**<sup>(16)</sup>

**3-Boston carpal tunnel syndrome questionnaire (BCTQ)**<sup>(17)</sup>

**4. Visual analogue scale(VAS) for pain and, paraesthesia.**<sup>(18,19)</sup>

**Routine nerve conduction study:**

**General considerations**

1- Reassurance of the patient and explanation of the procedure.

2- The studies were performed at warm room 22-24 ° c, which was controlled by the air conditioning.

Using a Nihon kohden Neuropack 2 electromyography (EMG) machine, 2 channels, surface electrodes were used for:

- Median and ulnar motor nerves conduction study.
- Median and ulnar sensory nerves conduction study.
- F- wave for median and ulnar nerves if indicated to exclude proximal lesion.

**I) Motor conduction study of the Median nerve:**

DML, amplitude and MCV of the median nerve were estimated. The active electrode was placed on the motor point of the APB muscle (on thenar eminence just lateral to midpoint of 1st metacarpal bone) and the reference electrode was placed on the distal phalanx of the thumb (3-4 cm distal to the active electrode on the palmar aspect of the thumb). The ground electrode was placed between the active and the stimulating electrode. The nerve was stimulated supramaximally at the wrist 8 cm proximal to the active electrode just lateral to PL or at midline of forearm (if PL absent) and at the elbow medial to brachial artery pulsation<sup>(20)</sup>

***2-Motor nerve conduction study of the ulnar nerve: -***

DML, amplitude and MCV of the ulnar nerve were estimated. The active electrode was placed on the motor point of the abductor digiti minimi muscle (on hypothenar eminence just medial to mid-

point of 5th metacarpal bone) and the reference electrode was placed 3-4 cm distal to the active electrode. The ground electrode was placed between the active and the stimulating electrode. The nerve was stimulated supramaximally at the wrist 8 cm proximal to the active electrode just lateral to FCU tendon and below the elbow at the medial epicondyle. <sup>(20)</sup>

## **II) Sensory conduction study of Median nerve:**

Amplitude, and SCV of the median nerve were estimated. The active electrode was placed on the proximal phalanx of the thumb and the reference electrode was placed 3-4cm distal to the active electrode (over distal phalanx of the thumb). The ground electrode was placed between the active and the stimulating electrode. The nerve was stimulated 10 cm proximal to the active electrode. <sup>(21)</sup>

## **2- Sensory conduction study of Ulnar nerve:**

Amplitude, and SCV of the ulnar nerve were estimated. The active electrode was placed on the proximal phalanx of the little finger and the reference electrode was placed 3-4cm distal to the active electrode (over distal phalanx of the little finger). The ground electrode was placed between the active and the stimulating electrode. The nerve was stimulated 12 cm proximal to the active electrode. <sup>(22)</sup>

## **F wave study:** <sup>(21)</sup>

- 1) F-wave of median nerve: recorded from APB and stimulated at the wrist.
- 2) F-wave of ulnar nerve: recorded from abductor digiti minimi and stimulated at the wrist.

## **Electrophysiological grading of CTS** <sup>(15)</sup>

- Negative CTS:** normal findings on all tests (including comparative tests).
- Minimal CTS:** abnormal findings only on comparative tests.
- Mild CTS:** SCV slowed in the finger–wrist tract with normal DML.
- Moderate CTS:** SCV slowed in the finger–wrist tract with increased DML but <6ms.
- Severe CTS:** absence of sensory response in the finger–wrist tract and / or increased DML  $\geq$ 6 ms.
- Extreme CTS:** absence of thenar motor response.

**Musculoskeletal Ultrasound (US):** The ultrasound evaluation was performed on the same day of electrophysiological evaluation using SAMSUNG MEDISON (UGEO H60

The patients were seated facing the doctor while their forearms in extended supination position, their wrists in neutral position and their fingers placed on the table in semi extended

position. The transducer was placed directly on the patient's skin with gel. For the longitudinal scan of the median nerve, the probe was placed at the midline with the center of the probe at the distal wrist crease. This provided an initial general overview of the median nerve. For the transverse scan, the probe was kept directly perpendicular to the long axis of the median nerve.<sup>(23)</sup>

**The median nerve was examined to determine the followings :<sup>(24)</sup>**

- 1- **Cross sectional area (CSA)of median nerve:** was calculated at the level of the pisiform bone using the continuous tracing method of the nerve circumferences excluding the hyper echoic epineural rim, it is calculated in mm<sup>2</sup>. The median nerve is abnormally enlarged if its CSA was greater than 9 mm<sup>2</sup> at the level of the pisiform.
- 2- **Flattening ratio(FR):**the ratio between the transverse diameter and anteroposterior diameter of the median at the level of hamate was calculated. Normally up to 4 is best obtained at the level of the hamate.

**Preparation of PRP:** Double centrifugation technique was used to concentrate the platelets from autologous blood by Centrifuge EBA 21 Hettich ZENTRIFUGEN.

**PRP method<sup>(25)</sup>**

- 1- 25 -30 ml of whole blood was obtained by venepuncture in 10% sodium citrate tubes. 0.1 ml sod. Citrate for each 1ml blood.
- 2 The blood should not be chilled at any time before or during platelet separation except for gentle shaking to mix the anticoagulant thoroughly with the blood.
- 3- First centrifugation of blood using a 'soft' spin 1800 revolution per minute (rpm) for 15 min. to create upper plasma , middle buffy coat and lower red blood cell layer.
- 4- The supernatant plasma was transferred containing platelets into another sterile tube (without anticoagulant) by using a sterile pipette
- 5- At a higher speed (a hard spin)3200 rpm for 10 min. the second centrifugation of the supernatant plasma.
- 6-The lower 1/3rd is PRP and upper 2/3rd is platelet-poor plasma (PPP). At the bottom of the tube, platelet pellets are formed.
- 7- Platelet-poor plasma was removed and the platelet pellets were suspended in a minimum quantity of plasma (2-3mL) by gently shaking the tube.

**Technique of PRP & perineural injection**

The ultrasound-guided injection of PRP or D5W was performed with the wrist slightly extended and, the palm facing upwards the MN was identified at the inlet of the proximal carpal tunnel (pisiform level). The ultrasound-guided injection was conducted using the in-plane ulnar approach. The ulnar artery was identified using doppler imaging, and a 25-gauge needle was passed from the ulnar side of the wrist toward the MN. After placing the needle tip on the MN, 2 mL of PRP or D5W was injected to remove the nerve from the flexor retinaculum via hydrodissection. An additional 1 mL of PRP or D5W was delivered to the inferior part of the MN and the MN was peeled from the underlying subsynovial connective tissue. After this, the entire carpal tunnel was scanned to ensure that the PRP had spread throughout the proximal-to-distal area of the carpal tunnel.

### **Post procedure Protocol:**

All patients were observed for 10 minutes after injection for possible bleeding or dysesthesia. Ice pack application was done for 10-15 min.

The patients were recommended to avoid over-using wrist and, activities needing good hand grip activities for 24hrs-72hrs then limiting their activities for 2 weeks.

### **Statistical analysis of the data**

Data were fed to the computer and analyzed using IBM SPSS software package version 20.0. (Armonk, NY: IBM Corp). The Kolmogorov- Smirnov was used to verify the normality of distribution of variables, Comparisons between groups for categorical variables were assessed using **Chi-square test (Fisher)**. **Student t-test** was used to compare two groups for normally distributed quantitative variables. **Mann Whitney test** was used to compare between two groups for not normally distributed quantitative variables. **Paired t-test** was assessed for comparison between two periods for normally distributed quantitative variables, While **Wilcoxon signed ranks test** was assessed for comparison between two periods for abnormally distributed quantitative variables. Significance of the obtained results was judged at the 5% level

### **RESULTS**

This study included 3 male patients (10%) and 27 female patients (90%) in group 1. 2 male patients (6.7%) and 28 female patients (93.3%) in group 2. The patient's age ranged from 24-65 years, with a mean age of  $45.30 \pm 9.69$  years in group 1 and, ranged from 26-62 years, with a mean age of  $43.23 \pm 9.19$  years in group 2.

In our study most of our patients were housewives, 23 patients (76.7%) in group I and, 27 patients (90%) in group II.

We had 28 right-handed patients (93.3%) and 2 left handed patients (6.7%) in group I and 27 right handed (90%) and 3 lefthanded patients (10%) in group II. In group I 26 patients were unilateral, and 4 patients were bilateral while in group II 25 patients were unilateral and 5 patients were bilateral.

**Table (1): Comparison between the two studied groups according to different parameters**

		<b>Group 1</b>	<b>Group 2</b>	<b>U</b>	<b>P</b>
		<b>(n = 34)</b>	<b>(n = 35)</b>		
<b>VAS for pain</b>	<b>Before</b>				
	Min. – Max.	6 – 9	6 – 9	5	0
	Mean ± SD.	7.15 ± 0.89	7.20 ± 0.96	84.500	.895
	Median (IQR)	7 (6 – 8)	7 (6.50 – 8)		
	<b>After</b>				
	Min. – Max.	1 – 4	2 – 5	3	0
	Mean ± SD.	2.26 ± 0.99	39 ± 0.78	19.0*	.001*
Median (IQR)	2 (2 – 3)	3 (3 – 4)			
	<b>p<sub>1</sub></b>	<0.001*	<0.001*		
<b>VAS for parasthesia</b>	<b>Before</b>				
	Min. – Max.	6 – 9	6 – 9	4	0
	Mean ± SD.	6.91 ± 0.75	7.26 ± 0.98	84.0	.153
	Median (IQR)	7 (6 – 7)	7 (7 – 8)		
	<b>After</b>				
	Min. – Max.	1 – 4	2 – 5	2	<
	Mean ± SD.	2.15 ± 0.86	33 ± 0.75	68.500*	0.001*
Median (IQR)	2 (2 – 3)	3 (3 – 3)			
	<b>p<sub>1</sub></b>	<0.001*	<0.001*		
<b>Symptoms severity score (SSS)</b>	<b>Before</b>				
	Min. – Max.	26 – 45	27 – 44		
	Mean ± SD.	34.44 ± 56	35.80 ±	1	0
	Median (IQR)	33.50 (31 – 38)	35 (33 – 39.50)	.172	.245
	<b>After</b>				
	Min. – Max.	11 – 33	18 – 35	2	0
	Mean ± SD.	24.50 ± 5.26	27.54 ± 4.80	.511*	.014*
Median (IQR)	25 (22 – 29)	27 (24 – 31.50)			
	<b>p<sub>1</sub></b>	<0.001*	<0.001*		
<b>Functional severity score (FSS)</b>	<b>Before</b>				
	Min. – Max.	18 – 33	20 – 33		
	Mean ± SD.	25.74 ± 4.20	26.80 ± 3.54	1	0
	Median (IQR)	25 (24 – 28)	27(24.50 – 29)	.140	.258
	<b>After</b>				
	Min. – Max.	8 – 27	13 – 30	3	0
	Mean ± SD.	18.53 ± 4.23	21.83 ± 3.54	.516*	.001*
Median (IQR)	19.50 (15 – 1)	22 (20 – 24.50)			
	<b>p<sub>1</sub></b>	<0.001*	<0.001*		
<b>L</b>	<b>Before</b>				

	Min. – Max.	5.60 – 8.20	5.80 – 8.50		
	Mean ± SD.	72 ± 0.77	6.93 ± 0.84	0	0
	Median (IQR)	7(6.40 – 7.50)	6.60(6.22 – 7.60)	.462	.646
	<b>After</b>				
	Min. – Max.	42 – 7.6	4.60 – 8		
	Mean ± SD.	6 ± 0.9	5.92 ± 0.85	0	0
	Median (IQR)	6.10(5.40 – 6.50)	5.90(5.20 – 6.50)	.369	.714
	<b>p<sub>1</sub></b>	<0.001*	<0.001*		
<b>AMP (mv)</b>	<b>Before</b>				
	Min. – Max.	0.93 – 6.5	1.47 – 7.3		
	Mean ± SD.	3.71 ± 1.59	3.76 ± 1.77	5	0
	Median (IQR)	3.60 (2.6 – 4.9)	3.90 (1.92 – 5.50)	85.0	.904
	<b>After</b>				
	Min. – Max.	1.20 – 7	1.13 – 7.1		
	Mean ± SD.	4.93 ± 1.65	4.78 ± 29	5	0
	Median (IQR)	5.30 (4.6 – 6.3)	5.80 (3 – 6.60)	49.0	.581
	<b>p<sub>1</sub></b>	<0.001*	0.001*		

**U: Mann Whitney test**

p: p value for comparing between the studied groups

p<sub>1</sub>: p value for **Wilcoxon signed ranks test** for comparing between **before** and **after 3**

**months**

\*: Statistically significant at  $p \leq 0.05$

**Table (2): Comparison between the two studied groups according to different parameters**

	<b>Group 1</b> (n = 34)	<b>Group 2</b> (n = 35)	<b>T</b> <b>est of</b> <b>sig.</b>	<b>p</b>	
<b>SAMP (µv)</b>	<b>Before</b>				
	Absent	21(61.8%)	20(57.1%)	□	0
	Present	13(38.2%)	15(42.9%)	<sup>2</sup> =0.153	.696
	Min. – Max.	1.50 – 34	3.20 – 42.10		
	Mean ± SD.	11.74 ± 8.88	13.15 ± 10.35	U	0
	Median (IQR)	7.33 (6.7 – 15)	10.50 (7.42 – 12.85)	=90.0	.751
	<b>After</b>				
	Absent	8(23.5%)	8(22.9%)	□	0
	Present	26(76.5%)	27(77.1%)	<sup>2</sup> =0.004	.647
	Min. – Max.	2.30 – 29.80	5.50 – 40.10		
Mean ± SD.	12.63 ± 6.53	12.60 ± 7.63	U	0	
Median (IQR)	11 (8 – 17.60)	11 (8.60 – 14.15)	=0.332	.735	
<b>p<sub>1</sub></b>	0.028*	0.015*			

SCV (m/s)	<b>Before</b>					
	Absent	21(61.8%)	20(57.1%)	□	0	
	Present	13(38.2%)	15(42.9%)	<sup>2</sup> =0.153	.696	
	Min. – Max.	11.40 – 42	21.60 – 37.70			
	Mean ± SD.	25.35 ± 8.43	27.26 ± 4.12	U	0	
	Median (IQR)	26 (22.30 – 30.50)	26.40 (24.55 – 29.50)	=84.50	.555	
	<b>After</b>					
	Absent	8(23.5%)	8(22.9%)	□	0	
	Present	26(76.5%)	27(77.1%)	<sup>2</sup> =0.004	.947	
	Min. – Max.	21.60 – 41.70	21.10 – 39.50			
Mean ± SD.	26.97 ± 4.90	28.78 ± 4.57	U	0		
Median (IQR)	25.15 (23.40 – 29.20)	28.20 (25.5 – 32.20)	=249.50	.071		
	<sup>z</sup> p <sub>1</sub>	0.002*	0.001*			
CSA	<b>Before</b>					
	Min. – Max.	11 – 25	10 – 27			
	Mean ± SD.	166 ± 4.11	15.63 ± 3.87	U	0	
	Median (IQR)	14.50 (13 – 19)	15 (12.50 – 17.50)	=567.50	.740	
	<b>After</b>					
	Min. – Max.	8 – 22	8 – 21			
	Mean ± SD.	11.74 ± 3.61	12.14 ± 3.22	U	0	
	Median (IQR)	11 (9 – 14)	11 (10 – 13.50)	=0.517	.345	
		<sup>u</sup> p <sub>1</sub>	<0.001*	<0.001*		
	FR	<b>Before</b>				
Min. – Max.		2.17 – 6	2.17 – 5.8			
Mean ± SD.		3.76 ± 0.89	3.8 ± 0.7	t	0	
Median (IQR)		3.73 (3.12 – 4.23)	3.77 (2.98 – 4.33)	=0.166	.869	
<b>After</b>						
Min. – Max.		1.9 – 5.2	1.90 – 4.80			
Mean ± SD.		3.2 ± 0.73	3.24 ± 0.92	t	0	
Median (IQR)		3.29 (2.7 – 3.6)	3.1 (2.4 – 4)	=0.188	.852	
		<sup>u</sup> p <sub>1</sub>	<0.001*	<0.001*		

$\chi^2$ : Chi square test    t: Student t-test    Paired t-test    Z: Wilcoxon signed ranks test

p: p value for comparing between the studied groups

p<sub>1</sub>: p value for comparing between **before** and **after 3 months**

\*: Statistically significant at  $p \leq 0.05$

**Table (3): Comparison between the two studied groups according to improvement**

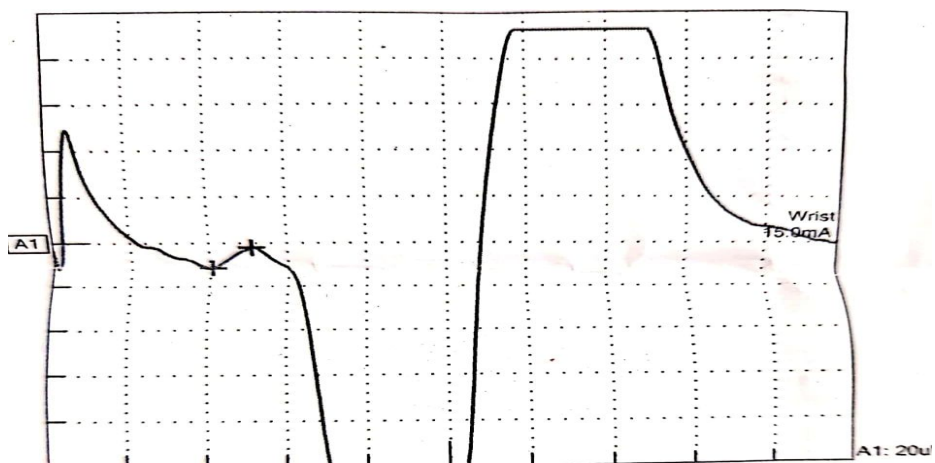
	Group 1 (PRP) (n = 34)	Group 2 (Dextrose) (n = 35)	$\chi^2$	P
--	------------------------------	-----------------------------------	----------	---

	No.	%	No.	%		
<b>DML (ms)</b>						
Non-Improvement	11	32.4	15	42.9	0.810	0.368
Improvement	23	67.6	20	57.1		
<b>AMP (µv)</b>						
Non-Improvement	10	30.3	13	37.1	0.355	0.551
Improvement	23	69.7	22	62.9		
<b>SAMP (µv)</b>						
Non-Improvement	13	38.2	11	31.4	0.352	0.553
Improvement	21	61.8	24	68.6		
<b>SCV (m/s)</b>						
Non-Improvement	11	32.4	9	25.7	0.369	0.543
Improvement	23	67.6	26	74.3		

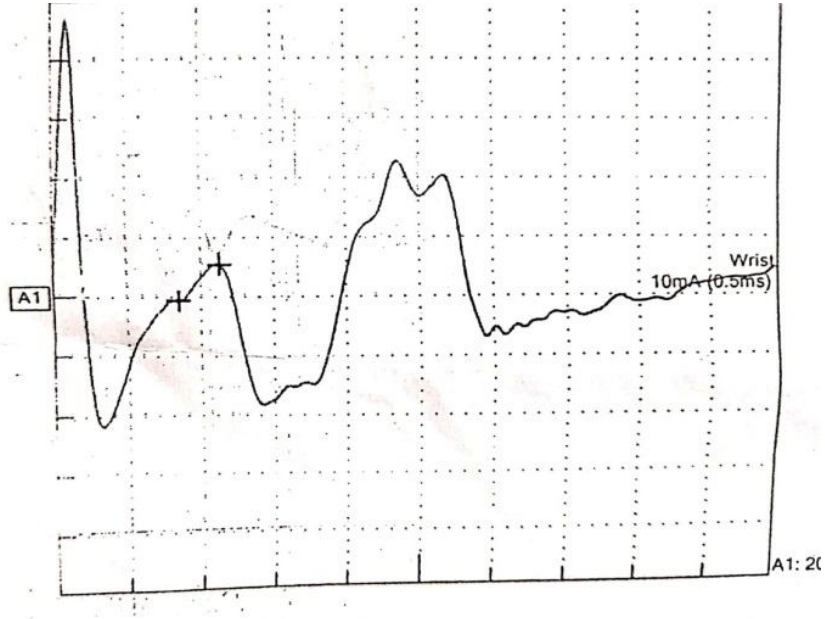
$\chi^2$ : Chi square test                      FE: Fisher Exact  
p: p value for comparing between the studied groups

## Cases

### Sensory conduction study:

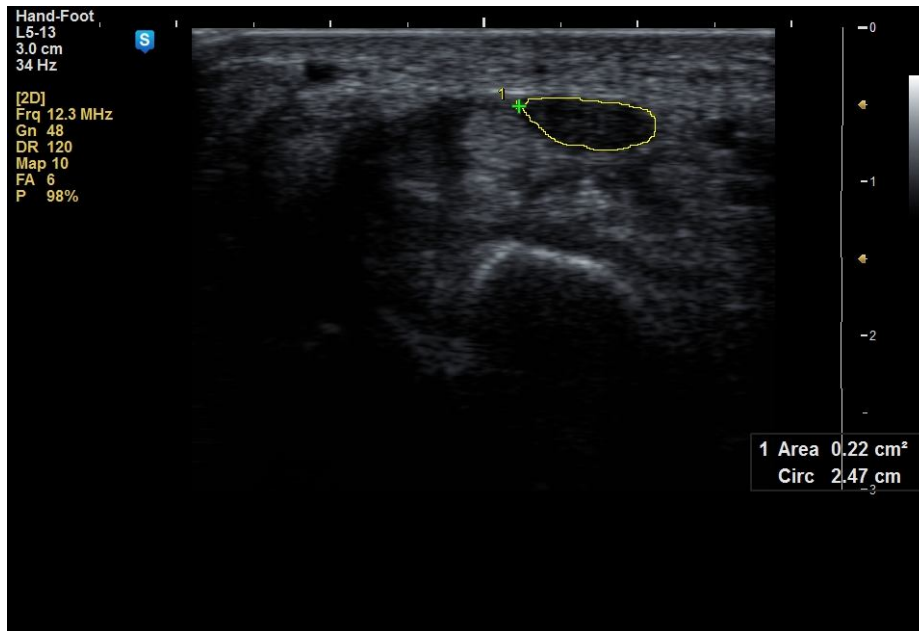


**Fig. (1):** Sensory conduction study of median nerve before treatment (latency =4.1 ms ,amplitude=10.1 microvolt, SCV=24.4 m/s)

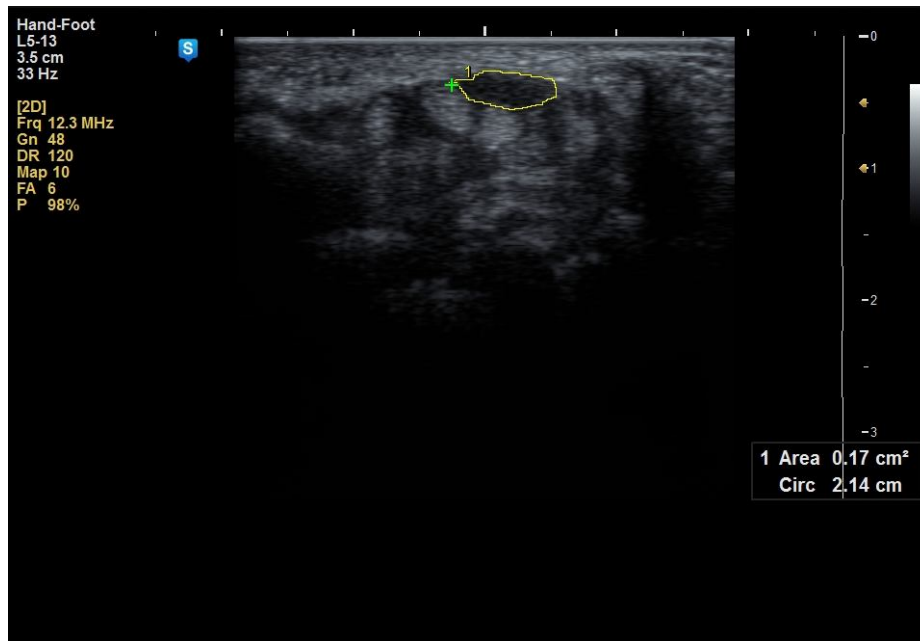


**Fig. (2):** Sensory conduction study of median nerve 3month after treatment (latency =3.4 ms ,amplitude=12.7 microvolt,SCV=29.2 m

**Ultrasound study:**



**Fig (3):** Transverse scan of median nerve showing CSA =22mm<sup>2</sup> before treatment



**Fig (4):** Transverse scan of median nerve showing CSA =17mm After treatment

## Discussion and Conclusion

In our clinical assessment, the results showed significant improvement in VAS for pain and parathesia after treatment and follow up period as compared to before treatment in both groups with insignificant difference between the 2 groups regarding VAS for pain before treatment while the difference was significant between the 2 groups regarding VAS for pain 3 months after treatment with better improvement in group 1.

The scores of symptoms severity scale (SSS) and functional status scale (FSS) of Boston carpal tunnel questionnaire (BCTQ) in PRP group were significantly reduced 3 months after injection.

There was significant improvement in BCTQ (FSS) 3 months after treatment as compared to before treatment in both groups. There was insignificant difference between the 2 groups regarding

BCTQ (FSS) before treatment while there was significant difference between the 2 groups 3 months after treatment with better improvement in group I.

There was insignificant difference between the 2 groups regarding BCTQ (SSS) before treatment while there was significant improvement in BCTQ (SSS) 3 months after treatment as compared to before treatment in both groups. There was significant difference between the 2 groups 3 months after treatment with better improvement in group I.

The present findings were in agreement with **Malahias et al. (2018)**<sup>(26)</sup> who found “significant improvement in VAS after 3 months of PRP injection in the treatment of CTS”.

In accordance, **Wu et al. (2017)**<sup>(27)</sup> reported that “the clinical outcomes are positive outcomes using PRP for patients with CTS with significant reduction in the VAS and BCTQ scores after 3 months of PRP injection . The results of this work are in partial agreement with **Raeissadat et al. (2018)**<sup>(28)</sup>, who showed significant improvement in the VAS and BCTQ after 10 weeks of single local injection of PRP using wrist splint in treatment of 21 patients with mild and moderate idiopathic CTS”.

**Raeissadat et al. (2018)**<sup>(28)</sup> reported that “the mechanism of PRP in CTS was uncertain and probably multifactorial; first, it could promote angiogenesis, neurogenesis, and regeneration via direct effects on the MN itself. Second, it could reduce the inflammation and swelling of the flexor tenosynovitis. Therefore, the PRP could decrease swelling of the flexor tendon and, it would result in reduction of intracarpal pressure exerted on the MN”.

Moreover, **Kuffler(2013)**<sup>(29)</sup> stated that “PRP may take effect by eliminating inflammation and initiating a series of biological processes such as tissue remodeling, wound repair, and axonal regeneration”.

“The application of PRP increases the number of nerve fibers after peripheral nerve re-anastomosis and can produce a neurotrophic effect, stimulating the proliferation of Schwann cells and myelination, which are important components during peripheral nerve repair”<sup>(30)</sup>

**Seyed. et al. (2018)**<sup>(31)</sup> reported that “PRP injection in patients diagnosed with CTS show significant improvements of pain and symptom severity and functional status according to the VAS and BCTQ and also electrophysiological parameters”.

**Yung .et al (2017)**<sup>(32)</sup> said that “perineural injection with dextrose 5% exhibited a significant reduction in Pain and disability, an improved electrophysiological response, and a decreased CSA of the MN for 6 months after treatment. The mechanism underlying the effects of PIT with Dextrose is unknown and may be multifactorial. Dextrose can reduce neurogenic inflammation via the inhibition of capsaicin-sensitive receptors (e.g., transient receptor potential vanilloid receptor-1) to stop the secretion of both substance P and calcitonin gene-related peptide, which are known to induce pain and swelling of the nerve and/or surrounding tissue”.

**Yung .et al (2018)**<sup>(33)</sup> reported that “dextrose and corticosteroid injection in mild to moderate CTS showed significant improvement clinically, electrophysiologically and CSA. The dextrose group exhibited significant reduction in pain and disability, compared to the steroid group at 4- and 6-months post injection. There was significant improvement in the dextrose group, in the pain and disability than steroid group”.

**Regarding the electrophysiological findings** there was significant improvement in DML of the median nerves 3months after treatment as compared to before treatment in both groups. There was insignificant difference between the 2 groups regarding DML of the median nerves before treatment.

There was significant improvement in the amplitude of the median nerves 3months after treatment as compared to before treatment in both groups. There was insignificant difference between the 2 groups regarding amplitude of the median nerves before treatment.

Regarding sensory conduction study of the median nerves there was significant improvement in sensory amplitude and conduction velocity of the median nerves 3months after treatment as compared to before treatment in both groups. There was insignificant difference between the 2 groups regarding sensory amplitude and conduction velocity of the median nerves before treatment.

These results are in agreement with **Seyed et al. (2018)**<sup>(31)</sup> who reported that “PRP injection in patients diagnosed with mild and moderate CTS show significant improvements of electrophysiological parameters (SNAP and CMAP)” and also with **Wu ,et al .( 2017)**<sup>(27)</sup> who reported significant improvement in SCV and DML of median nerve after PRP injection during the 6-month follow-up. Also our results coincided with **Esam et al (2018)**<sup>(34)</sup> who reported that “PRP injection in mild to moderate CTS showed a significant improvement in latency, amplitude and velocity of both SNAP and CMAP of the median nerve after 3 months of injection”.

**Ming et al (2017)**<sup>(35)</sup> reported that “there was insignificant difference between the PRP injection and dextrose 5% injection in CTS in electrophysiological study of the median nerve. The evaluation was performed pretreatment as well as on the 1st, 3rd, and 6<sup>th</sup> months after the injection”.

**Regarding musculoskeletal Ultrasoundfindings** there was significant improvement in cross sectional area (CSA) and (FR) of the median nerves 3months after treatment as compared to before treatment in both groups. There was insignificant difference between the 2 groups regarding CSA and FR of the median nerves beforeand aftertreatment.

**Michael et al (2015)**<sup>(36)</sup> who used the ultrasound measurement of CSA of the median nerve to evaluate the CTS, before, after the injection and during follow-up favored the use of the ultrasound CSA in the diagnosis of CTS and for guided injections into the carpal tunnel. They suggested that the changes in CSA seemed to be due to cascade of the biological response to compression in peripheral nerves including endoneurial edema, demyelination, inflammation, distal axonal degeneration, fibrosis, growth of new axons, remyelination, and thickening of the perineurium and endothelium. . They noticed that PRP injection cause a higher decrease in the mean swelling of the median nerve into the CT (decrease in the final CSA), which explained the therapeutic effect of PRP injection in CTS.

**Wu, et al. (2017)**<sup>(27)</sup> reported that injection of PRP caused significant decrease in CSA of the MN in CTS and, it seemed more pronounced with a longer follow-up duration.

**Yung et al (2017)**<sup>(32)</sup> found that perineural injection with dextrose 5% in CTS decreased CSA of the MN for 6 months after treatment and exhibited a significant improvement in electrophysiological response ((DML and SCV of median nerve).

**Yung-T.et al (2018)**<sup>(33)</sup> reported that single perineural dextrose 5% injection lead to significant reduction in pain and disability and CSA of median nerve compared to corticosteroid and, reported a trend of improved electrophysiological parameters (DML and SCV of median nerve) from the 4th month post injection. Considering the side effects of corticosteroid, they suggested that dextrose 5% is a better choice for perineural injection, for patients with CTS.

**Hashim et al (2020)**<sup>(37)</sup> mentioned significant improvement in all the parameters (BCTQ, VAS and DML)at 1.5 and 3 months of follow-up after injection with PRP compared with the baseline and, this was superior to the corticosteroid group.

In addition, **Senna et al (2019)** <sup>(38)</sup> reported “significant improvement in the clinical manifestations, the electrodiagnostic parameters of the median nerve (MN), and the median nerve cross sectional area (CSA) at 1 month and 3 months post-injection evaluation with PRP injection in comparison to baseline”.

**Atwa et al(2019)** <sup>(39)</sup> concluded that “single local injection of the PRP to be superior to steroid in the treatment of CTS, showing more improvement clinically as regard the pain and function and electrophysiologically” .

**Ming-J .et al (2017)** <sup>(35)</sup> reported that “the PRP had a significantly reduction of VAS score, BCTQ and CSA of median nerve than the Dextrose group. There was insignificant difference between the 2 groups in electrophysiological study of the median nerve and demonstrated that ultrasound-guided perineural injection with PRP or D5W is an effective and worthwhile intervention for patients with CTS. However, The PRP had a significantly noticeable reduction of CSA of median nerve than the dextrose 5%”.

**Shen et al (2019)** <sup>(40)</sup>“Compared PRP with the dextrose in CTS, the PRP group demonstrated significant reductions in Boston Carpal Tunnel Syndrome Questionnaire function at 3 months, distal motor latency at 6 months, and CSA at 3 and 6 months . A single perineural injection of PRP reduced the CSA of the median nerve more effectively than injection of D5W at 3- and 6-months post injection for patients with moderate CTS”.

**Karads et al. (2011)** <sup>(41)</sup> reported that “ultrasound-guided nerve hydrodissection is better than blind injection for removing surrounding tissues from the MN especially the intracarpal tendons”.

The hydrodissection could also contribute some benefits. The hypothesized possible causes based on the significantly reduced CSA of the MN and improved electrophysiological studies.

“Nerve hydrodissection is used to avoid nerve trauma and detach soft tissues, increasing the passage of nerve impulses and limiting ischemic nerve damage”. <sup>(42)</sup>

**Wu et al. (2019)** <sup>(43)</sup> found “greatest improvement in symptoms and, CSA in their study at 1 and 3 months after hydrodissection and stated that rapid improvement might result primarily from nerve hydrodissection and neurogenic antiinflammation of PRP or D5W”.

In our study, marked clinical improvement occurred in both groups for severe CTS. Our findings are compatible with that of **Uzun et al. (2017)** <sup>(30)</sup> “In that the improvement in symptoms

was not correlated with the improvement of electrophysiological measurements. This lack of association between the symptoms improvement and the electrophysiological testing improvement was not surprising since routine electrophysiological testing mainly evaluate the large myelinated rather than the small sensory fibers that can be involved in production of many CTS symptoms. It seems that the electrophysiological testing had a limited role in prediction of the therapeutic outcomes in CTS following surgery or conservative interventions”.

Treatments of carpal tunnel syndrome should focus not only on relief of symptoms but also enhancing the regeneration of nerve tissue and completely eliminate the causes of compression. Indeed, PRP has a higher concentration of growth factors after centrifugation. Also, the hydrodissection obtained from dextrose injection can reduce neurogenic inflammation.

This was demonstrated by the significant improvements in clinical, electrophysiological and ultrasound studies in both groups even though they suffered from severe carpal tunnel syndrome.

### **Ethival Approval**

The study was accepted by Tanta University's Faculty of Medicine's Local Research Ethics Committee.

### **Consent**

As per international standard or university standard, patients' written consent has been collected and preserved by the author(s).

## **Reference**

1. Ghasemi-Rad M, Nosair E, Vegh A, et al. A handy review of carpal tunnel syndrome: From anatomy to diagnosis and treatment. *World journal of radiology*. 2014;6(6):284-300.
2. Burton C, Chesterton S and, Davenport G. Diagnosing and managing carpal tunnel syndrome in primary care. *British Journal of General Practice*. 2014; 64(622):262-3.
3. Padua L, Coraci D, Erra C, et al. Carpal tunnel syndrome: clinical features, diagnosis, and management. *The Lancet Neurology*. 2016;15(12):1273-84.

4. Nigel L. Ashworth. Carpal Tunnel Syndrome. *BMJ Clin Evid.* 2014;2014-1114.
5. Nathan A, Meadows D and, Istvan A. Predictors of carpal tunnel syndrome: an 11-year study of industrial workers. *The Journal of hand surgery.* 2002;27(4):644-51.
6. Jablecki C, Andary M, Floeter M, et al. Second american academy of electodiagnosis medicine literature review of the usefulness of nerve conduction studies and needle electromyography for the evaluation of patients with carpal tunnel syndrome. *Muscle & Nerve.* 2002; 26(9):24-78.
7. Keith W, Masear V, Chung K, et al. Diagnosis of carpal tunnel syndrome. *The Journal of the American Academy of Orthopaedic Surgeons.* 2009;17(6):389-396.
8. Chang K, Hung C and, Özçakar L. Snapping thumb and superficial radial nerve entrapment in De Quervain disease: ultrasound imaging/guidance revisited. *Pain Medicine.* 2015;16(11):2214-15.
9. Benson S, Bare A, Nagle J, et al. Complications of endoscopic and open carpal tunnel release. *Arthroscopy: The Journal of Arthroscopic & Related Surgery.* 2006;22(9):919-24.
10. Raeissadat A and, Reza Z. Study of long term effects of laser therapy versus local corticosteroid injection in patients with carpal tunnel syndrome. *Journal of lasers in medical sciences.* 2010;1(1):24-30.
11. Sampson S, Gerhardt M and, Mandelbaum B. Platelet rich plasma injection grafts for musculoskeletal injuries: a review. *Current reviews in musculoskeletal medicine.* 2008;1(3-4):165-74.
12. Osterman C, McCarthy B, Cote P, et al. Platelet-rich plasma increases anti-inflammatory markers in a human coculture model for osteoarthritis. *The American journal of sports medicine.* 2015;43(6):1474-84.
13. Kim M, Na Y and, Moon J, et al. Comparison on treatment effects of dextrose water, saline, and lidocaine for trigger point injection. *Journal of Korean Academy of Rehabilitation Medicine.* 1997;21(5):967-73.

Eileen C, Brian B, Weglein A, et al, Neural prolotherapy. *Clin Med.* 2011;3(2):639-643. .14

15. Padua L, Monaco M, Padua R, et al. Neurophysiological classification of carpal tunnel syndrome: assessment of 600 symptomatic hands. *The Italian Journal of Neurological Sciences*. 1997;18(3):145-50.
16. Scangas G, Lozan S and, Ring D. Disparity between popular (Internet) and scientific illness concepts of carpal tunnel syndrome causation. *The Journal of hand surgery*. 2008;33(7):1076-80.
17. Levine D, Simmons B, Koris M, et al. A self-administered questionnaire for the assessment of severity of symptoms and functional status in carpal tunnel syndrome. *The Journal of bone and joint surgery. American volume*. 1993;75(11):1585-92.
18. Wilder S, Seet R and, Lim E. Diagnosing carpal tunnel syndrome—clinical criteria and ancillary tests. *Nature Clinical Practice Neurology*. 2006;2(7):366-74.
19. Breivik E, Björnsson G and, Skovlund E. A comparison of pain rating scales by sampling from clinical trial data. *The Clinical journal of pain*. 2000;16(1):22-8.
20. Lew H and, Tsai S. Pictorial guide to nerve conduction techniques. *Practical electromyography*. Philadelphia: Lippincott Williams & Wilkins. 4<sup>th</sup> ed, 2007;chapter 9,page 213-55.
21. MacDermid J and, Doherty T. Clinical and electrodiagnostic testing of carpal tunnel syndrome: a narrative review. *Journal of Orthopaedic& Sports Physical Therapy*. 2004;34(10):565-88.
22. Chang M, Wei S, Chiang H, et al. Comparison of motor conduction techniques in the diagnosis of carpal tunnel syndrome. *Neurology*. 2002;58(11):1603-7.
23. Tsai N, Lee L, Huang C, et al. The diagnostic value of ultrasonography in carpal tunnel syndrome: a comparison between diabetic and non-diabetic patients. *BMC neurology*. 2013;13(1):1-8.
24. El-Shintenawy A, Kassem E, El-Saadany H, et al. Diagnostic potential of high resolution ultrasound and nerve conduction study in patients with idiopathic carpal tunnel syndrome. *The Egyptian Rheumatologist*. 2019;41(1):71-5.
25. Dhurat R and, Sukesh M. Principles and methods of preparation of platelet-rich plasma: a review and author's perspective. *Journal of cutaneous and aesthetic surgery*. 2014;7(4):189.

26. Malahias M, Nikolaou V, Johnson E, et al. Platelet-rich plasma ultrasound-guided injection in the treatment of carpal tunnel syndrome: A placebo-controlled clinical study. *Journal of tissue engineering and regenerative medicine*. 2018;12(3):e1480-8.
27. Wu Y, Ho T, Chou Y, et al. Six-month efficacy of platelet-rich plasma for carpal tunnel syndrome: a prospective randomized, single-blind controlled trial. *Scientific reports*. 2017;7(1):1-1.
28. Raeissadat S, Karimzadeh A, Hashemi M, et al. Safety and efficacy of platelet-rich plasma in treatment of carpal tunnel syndrome; a randomized controlled trial. *BMC musculoskeletal disorders*. 2018;19(1):1-6.
29. Kuffler D. Platelet-rich plasma and the elimination of neuropathic pain. *Molecular neurobiology*. 2013;48(2):315-32.
30. Piñeros A, Rodeheaver P and, Rodeheaver G. Octyl 2-cyanoacrylate for repair of peripheral nerve. *Annals of plastic surgery*. 2005;55(2):188-95.
31. Seyed A ,Afshin K , Masoud H .et al .Safety and efficacy of platelet-rich plasma in treatment of carpal tunnel syndrome; a randomized controlled trial. *BMC MusculoskeletDisord*. 2018; 19: 49.
32. Yung T ,Tsung Y , Yu C ,et al .Six-month Efficacy of Perineural Dextrose for carpal tunnel syndrome: A Prospective, randomized, double-blind, Controlled Trial *Mayo Clin Proc*. 2017;92(8):1179-1189.
33. Yung T, Ming J, Tsung Y ,et al .Randomized double-blinded clinical trial of 5% dextrose versus triamcinolone injection for carpal tunnel syndrome patients. *Annals of neurology*. 2018;84(4):601-10.
34. Esam T ,Asmaa M ,Ibrahim T. et al .Platelet-rich plasma versus corticosteroid injections for carpal tunnel syndrome: Clinical and electrophysiological study *The Egyptian Rheumatol*,2018. <https://doi.org/10.1016/j.ejr.2018.07.008>.
35. Ke M, Wu Y, Ho T, et al. Platelet-rich plasma versus 5% dextrose for mild-to-moderate carpal tunnel syndrome. *Ultrasound in Medicine and Biology*. 2017;43:S184.

36. Malahias M, Johnson E, Babis G, et al. Single injection of platelet-rich plasma as a novel treatment of carpal tunnel syndrome. *Neural regeneration research*. 2015;10(11):1856.
37. Hashim N, Fathy H, Esawy M, et al. Comparison of efficiency between platelet rich plasma and corticosteroid injection therapies in patients with carpal tunnel syndrome: a prospective randomized controlled study. *The Egyptian Journal of Neurology, Psychiatry and Neurosurgery*. 2020;56(1):1-8.
38. Senna M, Shaat R and, Ali A. Platelet-rich plasma in treatment of patients with idiopathic carpal tunnel syndrome. *Clinical rheumatology*. 2019;38(12):3643-54.
39. Atwa E, Esh A, Abdelal I, et al. Platelet-rich plasma versus corticosteroid injections for carpal tunnel syndrome: Clinical and electrophysiological study. *The Egyptian Rheumatologist*. 2019;41(3):237-41.
40. Shen Y, Li T, Chou Y, et al. Comparison of perineural platelet-rich plasma and dextrose injections for moderate carpal tunnel syndrome: a prospective randomized, single-blind, head-to-head comparative trial. *Journal of tissue engineering and regenerative medicine*. 2019;13(11):2009-17.
41. Karadas Ö, Tok F, Ulas ÜH, et al. The effectiveness of triamcinolone acetonide vs. procaine hydrochloride injection in the management of carpal tunnel syndrome: a double-blind randomized clinical trial. *American journal of physical medicine & rehabilitation*. 2011;90(4):287-92.
42. Osterman M, Ilyas A and, Matzon J. Carpal tunnel syndrome in pregnancy. *The Orthopedic clinics of North America*. 2012;43(4):515-20.
43. Wu Y, Chen S, Li T, et al. Nerve hydrodissection for carpal tunnel syndrome: a prospective, randomized, double-blind, controlled trial. *Muscle & nerve*. 2019;59(2):174-80.