

Original Research Article

Effect of Laparoscopic Ovarian Cystectomy of Endometriotic and Non-Endometriotic Cysts on Ovarian Volume, Ovarian Reserve and Ovarian Doppler Velocimetry

place is not mentioned :[1h]Comment

Abstract

Background: Laparoscopic ovarian cystectomy (LOC) is one of the most often performed and simplest gynaecological procedures. The aim of this study was to evaluate the change in ovarian reserve, ovarian volume and ovarian Doppler velocimetry after LOC, between endometrioma patients and other benign ovarian cysts.

Methods: Eighty participants were enrolled in this prospective cohort research. Aged 18-40 years suffering from unilateral ovarian cysts. Patients were classified into two equal groups: group I: unilateral (endometriotic cyst), and group II: unilateral (non-endometriotic cyst) each group was subdivided into 2 equal subgroups. Group I: subgroup A: stripping and subgroup B: cauterization. Group II: subgroup A: dermoid cysts and subgroup B: simple serous cyst.

Results AMH (antimullerian hormone) post operation and after 3 months were significantly higher in stripping than cauterization subgroups. AMH post operation and after 3 months, AFC (unilateral antral follicle counts) after operation and reduction in AFC were significantly lower in stripping subgroup in endometrioma than dermoid subgroup in non-endometrioma. AFC before operation, reduction in AMH post 3 months, reduction in AFC and reduction in ovarian volume were significantly lower in dermoid than simple cyst subgroups in non-endometrioma group. AFC after operation was significantly higher in dermoid than simple cyst subgroups in non- endometrioma group.

Conclusions: AMH was higher in stripping subgroup than cauterization subgroup in endometrioma group post-operatively. AFC was higher in simple subgroup than dermoid

subgroup in non-endometrioma group before operation, but no significant difference was noted after operation.

Keywords: Laparoscopic Ovarian Cystectomy, Endometriotic Cysts, Non-Endometriotic Cysts, Ovarian Volume, Ovarian Reserve, Ovarian, Doppler Velocimetry

Introduction:

Laparoscopic ovarian cystectomy (LOC) is one of the most often performed and simplest gynecological procedures, and it is a reliable approach for determining the serial variation of serum antimullerian hormone (AMH), it depicts the ovarian reserve alterations following LOC ^[1].

The ovarian reserve is a term that refers to the population size of primordial follicles in the ovaries that is not growing or resting, determines, presumably, the number of follicular phase and their oocytes' "quality" or reproductive potential ^[2].

The primary factor affecting ovarian reserve is age, however, additional iatrogenic causes, like radiation, chemotherapy, surgery, and other systemic gonadotoxic drugs, also contribute to a reduction in ovarian reserve ^[3].

Over the years, a variety of approaches have been employed to determine ovarian reserve, and AMH is the most beneficial of all ovarian reserve tests as it is the only menstrual cycle-independent and easily quantifiable indicator of ovarian reserve ^[4].

Endometriosis is the occurrence of endometrial gland and stomas external to the uterine cavity. Endometriosis's true incidence is exceedingly difficult to compute; nevertheless, it is expected to afflict between 2% and 10% of women of reproductive age, and 50% of cases experience infertility ^[5].

In the majority of cases, endometrioma (also called an ovarian endometriotic cyst) is a pseudocyst created by enfolding from endometriotic implants, and a large endometrioma may develop as a result of a functioning ovarian cyst becoming involved in the endometriosis process ^[6].

Endometrioma resection is closely attributed to follicular deficiency and ovarian stromal injury. Numerous studies have demonstrated a link with LOC for endometrioma and loss of ovarian reserve postoperatively ^[7].

Numerous investigations have showed that a loss in ovarian reserve following LOC for endometrioma, as determined by repeated blood AMH levels, was more pronounced than a decrease in ovarian reserve following LOC for nonendometriotic cyst^[8].

Angiogenesis has been identified as a key element in the endometriosis pathogenesis. The peritoneal fluid of endometrioma patients included elevated amounts of angiogenic factors. New blood vessel development is required for the survival of endometriotic foci that have been implanted recently, additionally, they are selected via angiogenesis by endometriotic lesions^[9].

Additionally, it was observed that ablation of endometriomas altered ovarian colour Doppler velocimetry, resulting in an increase in the resistance index (RI)^[10].

The goal of this work was to evaluate the change in ovarian reserve, ovarian volume and ovarian Doppler velocimetry after LOC, between endometrioma and other benign ovarian cysts.

Patients and Methods:

Eighty participants were enrolled in this prospective cohort research aged 18 – 40 years suffering from unilateral ovarian cysts (endometriotic and non-endometriotic), AMH (anti-müllerian hormone) above 2ng/ml and history of regular menstrual cycle attending in the outpatient or the inpatient wards of the Department of Obstetrics and Gynecology, Tanta university.

An informed written consent from every patient included at this study. The consent was proved by the medical ethical committee of Tanta University Hospitals.

Exclusion criteria were age more than 40 years, AMH less than 2ng/ml, bilateral ovarian cysts, clinical or ultrasonic suspicion of ovarian malignancy, abnormal pelvic ultrasound findings other than ovarian cysts as uterine fibroids, adenomyosis, endometrial polyps, previous surgical treatment of any ovarian cysts and any contraindications of laparoscopy.

Patients were classified equally into two groups: group I: unilateral (endometriotic cyst), this group was subdivided into 2 equal subgroups; subgroup A: cases underwent laparoscopic stripping of the cyst and subgroup B: cases underwent laparoscopic cauterization of the inner surface of the cyst without cystectomy. Group II: patients with unilateral (non-endometriotic cyst) experienced laparoscopic stripping of this cyst. This group was subdivided into 2 equal subgroups; subgroup A: cases were dermoid cysts and subgroup B: cases were simple serous cyst. All patients underwent full history taking [history of previous ovarian surgery, menstrual history if there is any irregularity, infertility and type of dysmenorrhea], full general and abdominal and local examination and routine laboratory preoperative investigations.

AMH levels (Prior to surgery, between the third and fifth days of their spontaneous menstrual cycle, in the early follicular phase; Immediately after surgery within 1 week; months after surgery in the follow up visits). Beckman Coulter's AMH Gen II ELISA kit was used to determine AMH levels.

Transabdominal and transvaginal ultrasound examination (Gray scale B- mode and color Doppler sonography was first used. Using SAMSUNG H60 edition ultrasound).

Ultrasound imaging was used to determine the kind, size, and location of the ovarian cyst. Assessment of volume of diseased ovary by transvaginal ultrasound pre and postoperatively (within 10 days).

Assessment of Antral Follicular count of diseased ovary pre and postoperatively Harmonic imaging improved image quality by reducing artifacts. Color Doppler ultrasound on the ovarian vessels. Measurement of RI of ovarian vessels of diseased ovary pre and postoperatively by transvaginal ultrasonography. MRI (if needed only) to confirm type of the ovarian cyst.

Recording intraoperative findings regarding surgical procedure done intraoperative any complications postoperative recurrence.

Correlating the findings between the preoperative diagnosis using grey scale ultrasound – color Doppler ultrasound –MRI and the intraoperative findings.

Histopathological examination of all specimens.

Common surgical procedures done to the patient's group 1(All procedures were performed during the menstrual cycle's late follicular phase. A 10-mm trocar was placed following a sub umbilical skin incision, and pneumoperitoneum was produced and maintained at a pressure of 14 mm Hg using carbon dioxide insufflation. We used ef-mt camera and light source and Storz gas insufflator. Then, under direct laparoscopic monitoring, two more trocars (5 mm) were placed into both supra-inguinal locations.

Statistical methods

SPSS was used to conduct the statistical analysis v27 (IBM©, Chicago, IL, USA). Shapiro-Wilks used to test normality of numerical data. The mean and standard deviation of quantitative parametric data were calculated, and data analyzed using the unpaired student t-test or by ANOVA (F) test with post hoc test (Tukey) when more than two groups. When appropriate, qualitative variables were expressed as frequencies and percentages (%) and examined using the Chi-square or Fisher's exact test. Linear Correlation coefficient (r): used for detection of correlation between two quantitative variables in one group. A two tailed A P value of less than 0.05 was deemed statistically significant.

Results:

There is a negative correlation between age, size of the cyst and preoperative AMH (with increasing age and size of the cyst the AMH decreases). Figure 1

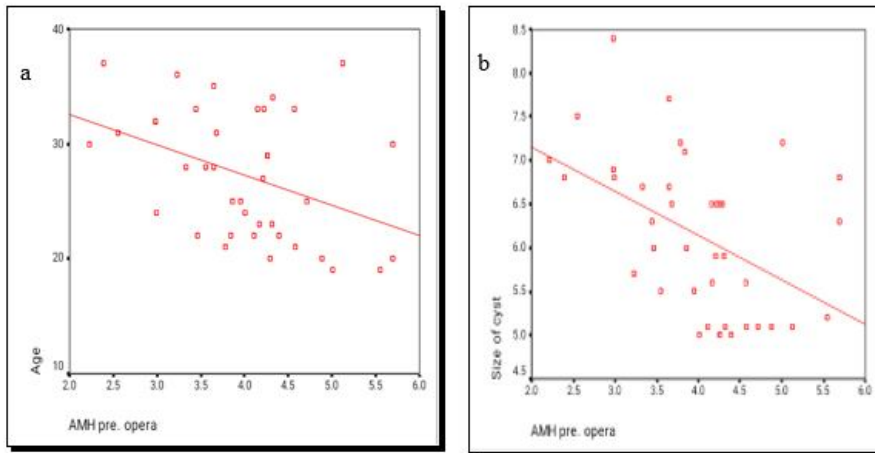


Figure 1: (a) Relation between age and AMH in the whole study group (b) Relation between size of the cyst and AMH in the whole study group

Age, size of cyst, AMH (pre-Operative), AFC before operation, reduction in ovarian volume, and operative reduction in ovarian doppler (RI) were non significantly different between stripping and cauterization subgroups in endometrioma group. AMH post operation and after 3 months were significantly higher in stripping than cauterization subgroups ($P < 0.05$). AFC after operation, reduction in AMH (immediate post op and post 3 months), reduction in AFC and recurrence were significantly lower in stripping than cauterization subgroups ($P < 0.05$).

Table 1

Table 1: Comparison between stripping and cauterization subgroups in endometrioma group according to age, size of cyst, AMH (pre, post and after 3 months), AFC (before and after operation), reduction in AMH (immediate post op., after 3 months), reduction in AFC, reduction in ovarian volume, operative reduction in ovarian doppler (RI) and recurrence

Endometrioma		Stripping	Cauterization	p. value
Age		27.20 ± 5.41	27.90 ± 5.51	0.609
Size of cyst		6.56 ± 1.13	5.81 ± 0.72	0.063
AMH	pre-Operative	3.86 ± 1.15	4.03 ± 0.69	0.457
	post-operative	2.06 ± 0.78	1.61 ± 0.58	0.010*

	after 3months	2.63 ± 0.82	1.86 ± 0.71	0.001*
AFC	Before operation	3.80 ± 1.99	4.50 ± 1.72	0.253
	After operation	1.80 ± 1.03	3.20 ± 1.62	0.001*
Reduction in AMH	Immediate Post op.	46.73 ± 9.19	60.83 ± 9.11	0.001*
	Post 3 months	31.93 ± 4.36	55.01 ± 10.41	0.001*
Reduction in AFC		22.33 ± 18.78	35.83 ± 22.73	0.012*
Reduction in Ovarian volume		53.23 ± 7.74	52.54 ± 4.60	0.664
Reduction in Ovarian Doppler (RI)		1.48 ± 7.18	3.35 ± 4.54	0.216
Recurrence		2 (10%)	12 (60%)	0.001*

Data are presented as mean ± SD or frequency (%), *: significant p value <0.05, AMH: antimullerian hormone, AFC: Antral follicle count, RI: intratumoral artery resistance index

Age, size of cyst, AMH (pre-Operative), AFC before operation, reduction in ovarian volume, and operative reduction in ovarian doppler (RI) were non significantly different between stripping subgroup in endometrioma group and dermoid subgroup in non-endometrioma group. AMH post operation and after 3 months, AFC after operation and reduction in AFC were significantly lower in stripping subgroup in endometrioma than dermoid subgroup in non-endometrioma (P< 0.05). Reduction in AMH (immediate post op and post 3 months), were significantly higher in stripping subgroup in endometrioma than dermoid subgroup in non-endometrioma (P< 0.05). Table 2

Table 2: Comparison between stripping subgroup in endometrioma group and dermoid subgroup in non-endometrioma group according to age, size of cyst, AMH (pre, post and after 3 months), AFC (before and after operation), reduction in AMH (immediate post op., after 3 months), reduction in AFC, reduction in ovarian volume and operative reduction in ovarian doppler (RI)

	Stripping	Dermoid	p. value
Age	27.20 ± 5.22	26.50 ± 5.78	0.624

Size of cyst		6.56 ± 1.09	6.36 ± 0.75	0.412
AMH	pre-Operative	3.86 ± 1.11	3.90 ± 0.56	0.457
	post-operative	2.06 ± 0.75	3.15 ± 0.66	0.010*
	after 3months	2.63 ± 0.79	3.70 ± 0.56	0.001*
AFC	Before operation	4.00 ± 1.70	3.50 ± 1.04	0.175
	After operation	1.80 ± 1.00	6.00 ± 1.76	0.001*
Reduction in AMH	Immediate Post op.	46.73 ± 8.87	19.70 ± 11.56	0.001*
	Post 3 months	31.93 ± 4.21	4.85 ± 7.49	0.001*
Reduction in AFC		22.33 ± 18.12	86.33 ± 85.21	0.012*
Reduction in Ovarian volume		53.23 ± 7.47	56.40 ± 10.39	0.180
Reduction in Ovarian Doppler (RI)		1.48 ± 6.93	2.91 ± 3.93	0.328

Data are presented as mean ± SD, *: significant p value <0.05, AMH: antimullerian hormone, AFC: Antral follicle count, RI: intratumoral artery resistance index

Age, size of cyst, and operative reduction in ovarian doppler (RI) were non significantly different between stripping subgroup in endometrioma group and simple cyst subgroup in non-endometrioma group. AMH pre, post operation and after 3 months, AFC before and after operation and reduction in Ovarian volume were significantly lower in stripping subgroup in endometrioma than simple cyst subgroup in non-endometrioma group (P< 0.05). Reduction in AMH (immediate post op and post 3 months) and reduction in AFC were significantly higher in stripping subgroup in endometrioma than simple cyst subgroup in non-endometrioma group (P< 0.05). Table 3

Table 3: Comparison between stripping subgroup in endometrioma group and simple cyst subgroup in non-endometrioma group according to age, size of cyst, AMH (pre, post and after 3 months), AFC (before and after operation), reduction in AMH (immediate post op., after 3 months), reduction in AFC, reduction in ovarian volume and operative reduction in ovarian doppler (RI)

	Stripping	Simple cyst	p. value
Age	27.20 ± 5.22	27.60 ± 5.46	0.773

Size of cyst		6.56 ± 1.09	5.81 ± 0.70	0.052
AMH	Pre-Operative	3.86 ± 1.11	4.24 ± 0.80	0.047*
	Post-Operative	2.06 ± 0.75	3.23 ± 0.78	0.001*
	After 3months	2.63 ± 0.79	3.60 ± 0.79	0.001*
AFC	Before operation	4.00 ± 1.70	5.10 ± 1.60	0.013*
	After operation	1.80 ± 1.00	4.70 ± 1.21	0.001*
Reduction in AMH	Immediate Post op.	46.73 ± 8.87	23.25 ± 14.52	0.001*
	Post 3 months	31.93 ± 4.21	14.76 ± 12.77	0.001*
Reduction in AFC		22.33 ± 18.12	1.94 ± 32.63	0.004*
Reduction in Ovarian volume		53.23 ± 7.47	65.50 ± 5.76	0.001*
Reduction in Ovarian Doppler (RI)		1.48 ± 6.93	3.02 ± 4.05	0.296

Data are presented as mean ± SD, *: significant p value <0.05, AMH: antimullerian hormone, AFC: Antral follicle count, RI: intratumoral artery resistance index

Age, size of cyst, AMH (pre-Operative, post-operative and after 3months) and reduction in ovarian doppler were non significantly different between dermoid and simple cyst subgroups in non- endometrioma group.

AFC before operation, reduction in AMH post 3 months, reduction in AFC and reduction in ovarian volume were significantly lower in dermoid than simple cyst subgroups in non-endometrioma group. AFC after operation was significantly higher in dermoid than simple cyst subgroups in non- endometrioma group (P< 0.05). Table 4

Table 4: Comparison between dermoid and simple cyst subgroups in non-endometrioma group according to age, size of cyst, AMH (pre, post and after 3 months), AFC (before and after operation), reduction in AMH (immediate post op., after 3 months), reduction in AFC, reduction in ovarian volume and operative reduction in ovarian doppler (RI)

Non-endometrioma	Dermoid	Simple cyst	p. value
Age	26.50 ± 5.99	27.60 ± 5.66	0.452
Size of cyst	6.36 ± 0.78	5.81 ± 0.72	0.119

AMH	pre-Operative	3.90 ± 0.58	4.24 ± 0.83	0.056
	post-operative	3.15 ± 0.68	3.23 ± 0.81	0.664
	after 3months	3.70 ± 0.58	3.60 ± 0.82	0.569
AFC	Before operation	3.50 ± 1.08	5.10 ± 1.66	0.001*
	After operation	6.00 ± 1.83	4.70 ± 1.25	0.001*
Reduction in AMH	Immediate Post op.	19.70 ± 11.99	23.25 ± 15.04	0.299
	Post 3 months	4.85 ± 7.77	14.76 ± 13.23	0.001*
Reduction in AFC		-86.33 ± 88.31	1.94 ± 33.82	0.001*
Reduction in Ovarian volume		56.40 ± 10.77	65.50 ± 5.97	0.001*
Reduction in Ovarian Doppler (RI)		2.91 ± 4.08	3.02 ± 4.20	0.915

Data are presented as mean ± SD, *: significant p value <0.05, AMH: antimullerian hormone, AFC: Antral follicle count, RI: intratumoral artery resistance index

Discussion

Endometriosis is the term used to describe the implantation of endometrial tissue outside the uterus, including stromal and epithelial tissues. Endometriosis is a leading cause of implant failure and infertility ^[11] by contrasting the potential risks associated with various treatment modalities, The research currently available suggests that laparoscopic techniques are advanced. Among the probable complications associated with laparoscopic surgery comprise injury to other organs resulting from the laparoscopic instruments, wound infection, a decreased concentration of AMH, bleeding, morbidity following surgery or prolonged stay, deep vein thrombosis, ileus, and/or other complication of medicine ^[12].

This study showed that there were insignificant differences between women of both groups according to AMH preoperative but there was significant difference immediately post-operative and after 3 months (AMH was higher in non-endometrioma group than endometrioma group postoperatively), p= 0.641 and 0.001.

Chae.^[13] agreed with current results and stated that serum AMH levels preoperatively did not differ involving the two groups ($p = 0.561$). Nevertheless, the endometrioma group had lower postoperative serum AMH levels than the teratoma group., with only a semblance of statistical significance ($p = 0.051$). The difference in the rate at which serum AMH levels decreased between the two groups was statistically significant ($p = 0.031$ and $p = 0.013$, respectively), suggesting that the endometrioma group experienced a faster decrease in serum AMH levels subsequent to surgery than the teratoma group.

Nankali et al.^[14] used meta-analysis to determine the effect of unilateral and bilateral laparoscopic endometriosis surgery on concentrations of AMH after three and six months, respectively. They agreed with our results and stated that both unilateral and bilateral laparoscopic surgery for endometriosis is helpful at lowering AMH levels, and both comparisons show a drop in levels of AMH. In this meta-analysis and systematic review (2.8 ± 0.11 before intervention, and 2.05 ± 0.13 after 3 months; and 3.1 ± 0.46 before intervention and 2.08 ± 0.31 after 6 months), and during the assessment of bilateral laparoscopic surgery for endometriosis (2.0 ± 0.08 before intervention, and 1.1 ± 0.1 after 3 months; and 2.9 ± 0.23 before intervention and 1.4 ± 0.19 after 6 months).

CO2 laser vaporization was investigated to determine if it offers better outcomes in the treatment of endometrioma regarding preserving ovarian reserve in comparison to standard cystectomy by Candiani et al.^[15]. A randomized clinical trial involving 60 participants was conducted at many centers. Computerized randomization was used to assign them in a 1:1 ratio to group 1 (laparoscopic stripping: cystectomy) or group 2 (non-laparoscopic stripping: cystectomy) (CO2 laser vaporization). 1st group patients experienced a standardised laparoscopic stripping procedure; group 2 patients in were subjected to cyst draining, biopsy, and vaporization of internal wall with a CO2 fibre laser. Prior to surgery and at the one- and three-month follow-up, Patients were subjected to pelvic ultrasound examinations to evaluate

the AFC and blood sample to ascertain the levels of AMH. They disagreed with us and stated that at three months, serum AMH levels were significantly lower in group 1 (from 2.6 ± 1.4 ng/mL at baseline to 1.8 ± 0.8 ng/mL at 3-month follow-up; 95 % CI: -1.3 to -0.2; P = 0.012) than in group 2 (from 2.3 ± 1.1 ng/mL at baseline to 1.9 ± 0.9 ng/mL at 3-month follow-up; 95% CI: -1 to -0.2; P = 0.09).

Amooee et al. ^[16] investigated AMH serum level as a predictor of ovarian reserve prior to and following surgical cystectomy. They recruited 60 dermoid cysts patients, having cystadenoma serous and cystadenoma mucinous. Serum AMH levels were determined prior to surgery and one- and three-months following cystectomy laparoscopically. Serum levels of AMH were compared prior to and following surgery, as well as across different forms of ovarian cysts. They disagreed with us and stated that After surgery, the serum AMH level decreased considerably nonetheless, it rebounded to 65% of its baseline level amount 3 months later. Reduced serum levels of AMH may contribute to reduced ovarian reserve following LOC. This can occur as a result of the use of thermocoagulation to attain hemostasis during the operation.

Karadag et al. ^[17] compared the effect the effect of laparoscopic cystectomy on ovarian reserve in patients with endometrioma and dermoid cysts. Ultrasonography was used to diagnose 36 individuals with endometrioma (group A) and 32 patients with dermoid cysts (group B). AMH levels were determined preoperatively, and for the ovarian side harboring the cyst, AFC were computed. All individuals underwent laparoscopic cystectomy using the stripping technique. After three months, all subjects underwent a re-evaluation between the third and sixth days of their menstrual cycle to ascertain their AFC and AMH levels. They disagreed with us and stated that the mean serum AMH and AFC concentrations preoperatively were significantly lower in group A than in group B (p=0.001, p=0.002), respectively. They agreed with us and stated that Serum AMH levels declined significantly

from 2.04 ± 0.68 to 1.47 ± 0.55 ($p=0.001$) in group A, and from 2.60 ± 0.57 to 2.17 ± 0.56 ; $p=0.001$ in group B, three months following surgery. AMH levels dropped significantly more in group A than in group B ($p=0.033$). Additionally, the reduction in AFC levels was much significantly greater in group A than in group B ($p=0.044$).

Statistical analysis of current study demonstrated that there was insignificant difference between stripping and cauterization according to AFC before operation but significant difference after operation (higher in cauterization subgroup than stripping subgroup after operation), $p= 0.410$ and 0.033 .

Rius et al. ^[18] conducted in a tertiary university hospital, a prospective, randomized, blinded, self-controlled pilot trial on consecutive patients with bilateral ovarian endometriomas ≥ 3 cm in diameter. Each patient had a CO₂ laser vaporization of one endometrioma and laparoscopic decapsulation of the contralateral endometrioma. They agreed with current results and stated that at baseline, there were in significant differences in levels of AFC across groups. At the 6-month follow-up, the laser-treated group had significantly higher AFC levels than the stripping method group.

Statistical analysis of current study demonstrated that there was insignificant difference between stripping and cauterization subgroups in endometrioma group according to ovarian volume and ovarian Doppler (RI) of diseased ovary before and after operation, $p= 0.676$, 0.308 , 0.418 and 0.726 .

Rius et al. ^[18] agreed with current results and stated that there were insignificant differences between group in baseline ovarian volume levels but disagreed with current results and stated that At six months, the laser-treated group had significantly more ovarian volume than the stripping procedure group.

Var et al. ^[19] disagreed with us and stated that after cystectomy and coagulation, postprocedural ovarian volumes were 6.27 ± 1.95 and 9.87 ± 2.01 , respectively. Cystectomy resulted in a decrease in ovarian volume as compared to coagulation.

Statistical analysis of current study demonstrated that there was a significant difference between stripping and cauterization subgroups in endometrioma group according to recurrence (recurrence was higher in cauterization subgroup than stripping subgroup after operation), $p = 0.019$.

Shaltout et al. ^[20] evaluated surgical efficacy in avoiding endometriomas recurrence following cautious laparoscopic management (cystectomy or drainage). Two hundred women were included in a randomised controlled trial (candidate for conservative laparoscopic management of ovarian endometriomas). They were randomly assigned to one of four groups: group C received laparoscopic cystectomy of the endometrioma, group D received laparoscopic drainage of the endometrioma, group CS received laparoscopic cystectomy of the endometrioma followed by insertion of surgical inside the remaining ovarian tissues, and group DS received laparoscopic drainage followed by insertion of surgical inside the cyst cavity. All patients were monitored for a period of two years & the primary outcome was recurrence of endometriomas in the ipsilateral ovary; & the secondary outcome was reassessment of postoperative ovarian reserve. They agreed with us and stated that In comparison to other groups, the surgically treated groups had a significantly lower risk of recurrence.

Limitations: The sample size was relatively small.

Conclusions:

AMH was higher in stripping subgroup than cauterization subgroup in endometrioma group post-operatively. AFC was lower in cauterization subgroup than stripping subgroup in endometrioma group after operation. Recurrence rate was higher in cauterization subgroup

than stripping subgroup in endometrioma group after operation. There were insignificant differences between dermoid and simple cyst subgroups in non-endometrioma group according to age, size of cyst, AMH pre-operative, post-operative and after 3 months, ovarian volume and Doppler of diseased ovary. AFC was higher in simple subgroup than dermoid subgroup in non-endometrioma group before operation, but no significant difference was noted after operation.

COMPETING INTERESTS DISCLAIMER:

Authors have declared that no competing interests exist. The products used for this research are commonly and predominantly use products in our area of research and country. There is absolutely no conflict of interest between the authors and producers of the products because we do not intend to use these products as an avenue for any litigation but for the advancement of knowledge. Also, the research was not funded by the producing company rather it was funded by personal efforts of the authors.

References:

1. Iwase A, Hirokawa W, Goto M, Takikawa S, Nagatomo Y, Nakahara T, et al. Serum anti-Müllerian hormone level is a useful marker for evaluating the impact of laparoscopic cystectomy on ovarian reserve. *Fertil Steril*. 2010;94:2846-9.
2. Findlay J, Hutt K, Hickey M, Anderson R. What is the "ovarian reserve"? *Fertil Steril* 2014;103:150-6.
3. Rasool S, Shah D. Fertility with early reduction of ovarian reserve: the last straw that breaks the Camel's back. *Fertility research and practice*. 2017;3:15-9.
4. La Marca A, Giulini S, Tirelli A, Bertucci E, Marsella T, Xella S, et al. Anti-Müllerian hormone measurement on any day of the menstrual cycle strongly predicts ovarian response in assisted reproductive technology. *Hum Reprod*. 2007;22:766-71.

5. Dunselman GA, Vermeulen N, Becker C, Calhaz-Jorge C, D'Hooghe T, De Bie B, et al. ESHRE guideline: management of women with endometriosis. *Hum Reprod.* 2014;29:400-12.
6. Hachisuga T, Kawarabayashi T. Histopathological analysis of laparoscopically treated ovarian endometriotic cysts with special reference to loss of follicles. *Hum Reprod.* 2002;17:432-5.
7. Somigliana E, Berlanda N, Benaglia L, Viganò P, Vercellini P, Fedele L. Surgical excision of endometriomas and ovarian reserve: a systematic review on serum antimüllerian hormone level modifications. *Fertil Steril.* 2012;98:1531-8.
8. Lee DY, Young Kim N, Jae Kim M, Yoon BK, Choi D. Effects of laparoscopic surgery on serum anti-Müllerian hormone levels in reproductive-aged women with endometrioma. *Gynecol Endocrinol.* 2011;27:733-6.
9. Seckin B, Oruc AS, Turkcapar F, Ugur M. The relation of pelvic pain and dense adhesions to Doppler ultrasound findings in patients with ovarian endometriomas. *Arch Gynecol Obstet.* 2013;287:723-8.
10. La Torre R, Montanino-Oliva M, Marchiani E, Boninfante M, Montanino G, Cosmi EV. Ovarian blood flow before and after conservative laparoscopic treatment for endometrioma. *Clin Exp Obstet Gynecol.* 1998;25:12-4.
11. Gmyrek GB, Sieradzka U, Goluda M, Gabrys M, Sozanski R, Jerzak M, et al. Flow cytometric evaluation of intracellular cytokine synthesis in peripheral mononuclear cells of women with endometriosis. *Immunol Invest.* 2008;37:43-61.
12. Suksompong S, Dejarkom S, Petyim S, Dangrat C, Orachon D, Choavaratana R. Ovarian reserve evaluation by anti-mullerian hormone in women undergoing laparoscopic cystectomy of endometrioma. *J Med Assoc Thai.* 2012;95:1389-95.

13. Chae H. Influence of Cyst Size on Ovarian Reserve After Unilateral Laparoscopic Ovarian Cystectomy for Endometrioma and Ovarian Mature Teratoma. *Res Sq.* 2019:520-3.
14. Nankali A, Kazeminia M, Jamshidi PK, Shohaimi S, Salari N, Mohammadi M, et al. The effect of unilateral and bilateral laparoscopic surgery for endometriosis on Anti-Mullerian Hormone (AMH) level after 3 and 6 months: a systematic review and meta-analysis. *Health Qual Life Outcomes.* 2020;18:314-9.
15. Candiani M, Ottolina J, Posadzka E, Ferrari S, Castellano LM, Tandoi I, et al. Assessment of ovarian reserve after cystectomy versus 'one-step' laser vaporization in the treatment of ovarian endometrioma: a small randomized clinical trial. *Hum Reprod.* 2018;33:2205-11.
16. Amooee S, Gharib M, Ravanfar P. Comparison of anti-mullerian hormone level in non-endometriotic benign ovarian cyst before and after laparoscopic cystectomy. *Iran J Reprod Med.* 2015;13:149-54.
17. Karadağ C, Demircan S, Turgut A, Çalışkan E. Effects of laparoscopic cystectomy on ovarian reserve in patients with endometrioma and dermoid cyst. *Turk J Obstet Gynecol.* 2020;17:15-20.
18. Rius M, Gracia M, Ros C, Martínez-Zamora M, deGuirior C, Quintas L, et al. Impact of endometrioma surgery on ovarian reserve: a prospective, randomized, pilot study comparing stripping with CO(2) laser vaporization in patients with bilateral endometriomas. *J Int Med Res.* 2020;48:627-9.
19. Var T, Batioglu S, Tonguc E, Kahyaoglu I. The effect of laparoscopic ovarian cystectomy versus coagulation in bilateral endometriomas on ovarian reserve as determined by antral follicle count and ovarian volume: a prospective randomized study. *Fertil Steril.* 2011;95:2247-50.

20. Shaltout MF, Elsheikhah A, Maged AM, Elsherbini MM, Zaki SS, Dahab S, et al. A randomized controlled trial of a new technique for laparoscopic management of ovarian endometriosis preventing recurrence and keeping ovarian reserve. J Ovarian Res. 2019;12:66-9.