

## Original Research Article

### **Evaluation of the hepatic effects of *Caladium hortulanum* Leaf Extract on Wistar Albino rats.**

#### **ABSTRACT**

This study evaluates the hepatic effects of *caladium hortulanum* leaf extract on wistar albino rats. A total of twenty-four (24) rats were randomly divided into 4 groups labeled A, B, C and D and kept in a well-ventilated room. Group A served as control and these rats were fed distilled water. Rats in the groups B, C, and D were given three (3) different doses of the leaf extract (1.5, 3.5 and 5.0mL/Kgbw) respectively. They were administered once daily for 14 and 28 days consecutively. Animals were sacrificed 24 hours after the last treatment. Blood samples were collected into heparinized sample bottles for analysis. All liver enzymes and histology results were normal for short term use in this study. Alkaline phosphatase was increased in a dose dependent manner when used in the long term. Histopathological changes were seen in all doses when *Caladium hortulanum* leaf extract was used in the long term. This suggests that this medicinal plant cause some degree of hepatic damage when used for continuously for long periods at a time. Care should therefore be taken with their use, prescriptions reviewed as needed and regular monitoring of liver function should be instituted.

**KEYWORDS:** CALADIUM HORTULANUM, HEPATIC, LEAF EXTRACT

#### **INTRODUCTION**

The impact of the COVID-19 pandemic on Nigeria has been widely studied in recent times. The Copenhagen Consensus Centre and the National Institute for Legislative and Democratic Studies (NILDS) reported that the lockdowns imposed in Nigeria led to a loss of 373.5 billion US Dollars. The social distancing measures that were instituted increased deaths from malaria, Tuberculosis, child malnutrition and disrupted health outreaches and economic activities (Joab-Peterside 2020; Orhero and Oghuvbu 2020).

Consequently, there was increased frustration amongst citizens in assessing routine health care services. Elective surgical cases were put off, hospitals had to choose between exposing seriously ill patients to potential COVID-19 infection and admitting for quality care (UNHCR 2020).

This led to an increased number of patients seeking alternative care with traditional medicine practitioners for ailments that they will visit a hospital for care (Joab-Peterside 2020). This is not to underestimate the importance of medicinal plants used by most of these practitioners in their practice (Simoben et al., 2020). These plants are also used conventionally in pharmaceuticals, cosmetics and food supplements industries (Wyk 2018). But there is a paucity of data on their effect on normal organ functioning especially when used at the concentrations used by these practitioners (Moyo et al., 2015; Oforibika and Oforibika 2020; Oforibika and Uzor 2020).

*Caladium hortulanum* is an ornamental plant which studies have shown to have antimicrobial properties (Wilkins 2019). Traditionally, it is widely used amongst traditional medicine practitioners both topically and in ingestible forms (Udo et al., 2020).

The liver is the powerhouse of metabolism in mammals. It is essential in activating and eliminating ingested substances that play different biological roles (Oforibika and Oforibika 2020). The increasing patronage of traditional medicine practitioners and the use of *caladium* in their prescriptions, led the researchers to study the impact of this plant on the liver.

## MATERIALS AND METHOD

**Plant Collection and Identification:** *Caladium hortulanum* leaves were purchased from a traditional medicine practitioner at Okujagu town in Port Harcourt Local Government Area of Rivers State.

The plant specimen was confirmed by a Botanist and fellow researcher.

**Sample Preparation:** The leaves were weighed, washed with distilled water and allowed to air dry. A new mortar and pestle were used to pulverize it and the sample was extracted with distilled water for 24 hours at 35.0°C. The extracts were filtered using a Muslim cloth and concentrated using a rotary evaporator (Buchi-Rotavapor -R110) at a low pressure.

leaves were weighed, thoroughly washed with distilled water and crushed with a blender. The sample gotten was diluted with distilled water to the concentrations required.

**Specimen (animal) used for the experiment:** twenty-four (24) albino rats were purchased from animal house of the Department of Biochemistry, University of Port Harcourt, Choba Park. The animals were fed with rat pellets, water and libitum.

**Chemicals and reagents:** All chemicals and reagents used in this study were obtained from Randox Laboratories UK.

**Preparation of Drug solution for administration:** 1.5ml/kg, 3.5ml/kg and 5.0ml/kg of the preparation was given to the rats each day after weighing depending on their respective groups. This was Calculated based on an approximation of the amount used in local prescriptions.

**Experimental procedure:** A total twenty-four (24) albino rats of weight range (140-194g/BW) were randomly divided into four groups labelled A, B, C and D where group A served as control and rats (n=3rats/dose) were treated with distilled water. Rats in groups B, C and D (n = 3 rats/dose) were orally treated with 3 different doses of the leaf extract 1.5ml/kgBW, 3.5ml/kgBW and 5.0ml/kgBW for 14 and 28 days respectively. Animals were sacrificed twenty-four (24) hours after last treatment

**Collection of blood and preparation of serum:** For 14 and 28 days, the rats in each group were taken out of their cages twenty-four (24) hours after the last dose of medication and put in desiccators filled with cotton wool that had been saturated in chloroform to anaesthetize. The jugular vein of the rat was severed using a surgical blade to extract the blood samples, which were then placed in anticoagulant sample bottles that had been coated with lithium-heparin. Plasma was extracted from the blood samples using an MSE Centrifuge spinning at 5000 rpm. Only the liver was removed from the dissected animal for pathological research. **Measurement of**

**AST(SGOT) AND ALT(SGPT):** The activities of alanine aminotransferase (ALT) and aspartate aminotransferase (AST) was analysed according to the method specified by Reitman and Frankel (1957).

**Measurement of ALP:** Plasma alkaline phosphatase activity was measured by the method of Rec (1972).

**Histological procedures and analysis:** The liver was cut on slabs about 0.5cm thick and fixed in 10% normal saline for a day after which they were transferred to 70% alcohol for dehydration.

The tissues were deposited into two changes of molten paraffin wax for 20 minutes each and then placed in an oven at 57 percent after passing through 90 percent alcohol and chloroform for varying amounts of time.

From a solid block of tissue, several sections, each 5 m thick, were cut off, stained with hematoxylin and eosin, then passed through a solution of equal parts xylene and alcohol. Once the tissues were free of the xylene, they were oven dried.

To show the cytoarchitecture of the liver, photomicrographs were made using a JVC colour video digital camera (JVC China) mounted on an Olympus light microscope (Olympus UK Ltd Essex, UK).

## RESULT AND DISCUSSION

**Table 1:** Liver enzymes (U/l) results on 14 days of exposure

Extract volume (ml/kgBW)	Aspartate Aminotransferase (AST U/l)	Alanine Aminotransferase (ALT U/l)	Alkaline Phosphatase (ALP U/l)
Control (distilled water)	100±10	25±8	50±10
1.5	98	27	32
3.5	104	30	40
5.0	103	50	46

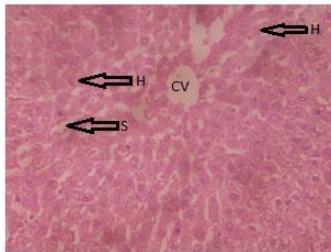
**Table 2:** Liver enzymes (U/l) results on 28 days of exposure

Extract volume (ml/kgBW)	Aspartate Aminotransferase (AST U/l)	Alanine Aminotransferase (ALT U/l)	Alkaline Phosphatase (ALP U/l)
Control (distilled water)	100±10	25±8	50±10

1.5	106	35	72
3.5	107	38	78
5.0	136	40	86

## Histology

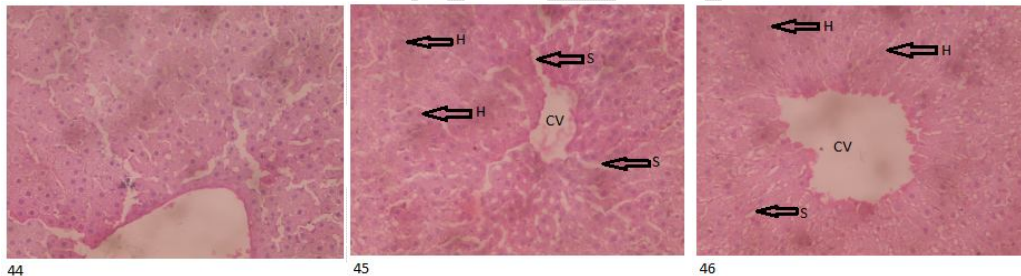
**Figure 1:** control



43

Slide 43- photomicrograph of normal liver tissue treated with distilled water showed a sinusoid, central vein and hepatocytes arranged in cords and radiating away from the central vein. (control).

**Figure 2:** result for 14 days of administration



44

45

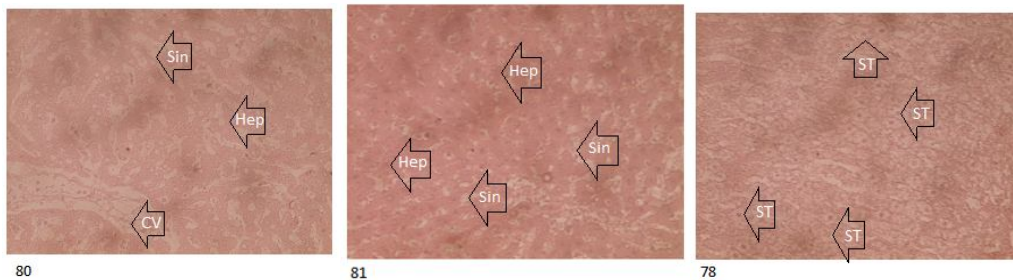
46

Slide 44- photomicrograph of normal liver tissue treated with 1.5ml/KgBW showed a sinusoid, central vein and hepatocytes arranged in cords and radiating away from the central vein.

Slide 45- photomicrograph of normal liver tissue treated with 3.5ml/KgBW showed a sinusoid, central vein and hepatocytes arranged in cords and radiating away from the central vein.

Slide 46- photomicrograph of histologically normal liver tissue treated with 5.0ml/KgBW showed a sinusoid, central vein and hepatocytes arranged in cords and radiating away from the central vein.

**Figure 3:** result for 28 days of administration



Slide 80- photomicrograph of histologically distorted liver tissue treated with 1.5ml/KgBW showed dilated sinusoids, congested central vein and normal hepatocytes.

Slide 81- photomicrograph of histologically distorted liver tissue treated with 3.5ml/KgBW showed dilated sinusoids, congested central vein and normal hepatocytes.

Slide 78- photomicrograph of markedly distorted liver tissue treated with 5.0ml/KgBW showed hepatocytes at different stages of steatosis.

Table 1 represents the result from wistar rats given *Caladium hortulanum* leaf extract for 14 days. All liver enzymes showed no significant changes as compared to the control.

Table 2 representing 28 days of administering the extract showed, Aspartate amino transferase and Alanine aminotransferase within normal limits as compared to the control. Alkaline phosphatase was significantly elevated when compared to the control.

Histology done showed normal liver architecture for 14 days of administration irrespective of dose, as seen in figure 2. On administering the sample for 28 days, features of liver abnormalities were seen as in figure 3. This ranged from steatosis at 5.0ml/KgBW dose to dilated sinusoids and congested central vein at both 1.5ml/KgBW and 3.5ml/KgBW doses.

In this research, both Aspartate aminotransferase and Alanine aminotransferase showed normal results irrespective of the duration of use. Alkaline phosphatase was normal for short term use but became elevated when used for longer. Histology followed similar pattern as Alkaline phosphatase. Results were normal in the short term but with prolonged use, changes in liver histology were seen irrespective of the dose given. This is similar to results from the research by (Omotoso et al., 2020) which showed dose dependent hepatopathy when *Caladium bicolor* leaf extracts were administered to wistar rats. This study on the other hand contrasts with a study done by (Abima et al 2020) which showed hepatoprotective features of *Caladium hortulanum* corm extracts on CCl<sub>4</sub> exposed hepatocytes.

There is a strong erroneous belief in Nigeria that most illnesses are caused by infections. Thus, caladium plant plays a prominent role in the prescriptions of most herbalists, irrespective of what is being treated (Essien et al., 2015). These prescriptions are hardly changed and thus patients stay on them for months to years (Oguntibeju et al., 2018). The liver with its strong regenerative capacity is able to bear with short-term use of these but not in the longterm. This research will be essential in drafting policies to guide the practice of these traditional medicine practitioners.

## CONCLUSION

This research has shown that *Caladium hortulanum* has the potential to cause damage to the liver when used for long periods. Better education and monitoring of prescriptions by licensed traditional medicine practitioners should be instituted

### Ethical Approval:

As per international standard or university standard written ethical approval has been collected and preserved by the author(s).

## REFERENCES

Abima Shazhni J.R., A. Renu, P. Vijayaraghavan, Insights of antidiabetic, anti-inflammatory and hepatoprotective properties of antimicrobial secondary metabolites of corm extract from *Caladium x hortulanum*, *Saudi Journal of Biological Sciences*, 25(8),2018, Pages 1755-1761 ,ISSN 1319-562X, <https://doi.org/10.1016/j.sjbs.2018.03.013>.

Essien, E. E., Jacob, I. E., & Thomas, P. S. (2015). Phytochemical composition, antimicrobial and antioxidant activities of leaves and tubers of three *Caladium* species. *Int J Med Plants Natural Prod*, 1(2), 24-30.

Joab-Peterside, S. (2021). Socio-economic implications of COVID-19 pandemic in Nigeria. *Global Journal of Social Sciences*, 20(1), 11-23.

Moyo, M., Aremu, A. O., & Van Staden, J. (2015). Medicinal plants: an invaluable, dwindling resource in sub-Saharan Africa. *Journal of Ethnopharmacology*, 174, 595-606.

Oforibika, G. A., & Oforibika, D. A. (2020). Evaluation of Liver Toxicity of Three Different Herbal Bitters (Confam, G. Winco and 1960 Roots) on Wister Albino Rats. *Pharmaceutical Science and Technology*, 4(1), 11.

Oforibika, G. A., & Oforibika, D. A. (2020). Estimation of Toxicity Level of Three Different Herbal Bitters (Confam, G. Winco and 1960 Roots) on some Serum Lipid Profile Parameters and the Heart of Wister Albino Rats. *Journal of Health Science Research*, 15-20.

Oforibika, G. A., & Uzor, C. A. (2020). Study of the renal function of Wistar albino rat treated with three different herbal bitters (Confam, G. Winco and 1960 Roots). *Direct Res. J. Public Health and Environ. Technol.* Vol.5 (1), pp.1-5, February 2020 ISSN 4372-2603 DOI: <https://doi.org/10.26765/DRJPHET85417040>

Oguntibeju O. O. (2018). Medicinal plants with anti-inflammatory activities from selected countries and regions of Africa. *Journal of inflammation research*, 11, 307–317. <https://doi.org/10.2147/JIR.S167789>

Omotoso, D. R., Brown, I., & Okojie, I. G. (2020). Sub-acute toxicity of *Caladium bicolor* (Aiton) leaf extract in Wistar rats. *Journal of Phytology*, 12, 77–81. <https://doi.org/10.25081/jp.2020.v12.6511>

Orhero A. E., and Oghuvbu E.S. 2020 the socioeconomic effects of COVID-19 global pandemic on nigerias development. *Journal of Danubian Studies and Research* 10 (1) 509-520

Simoben, C. V., Qaseem, A., Moubock, A. F., Telukunta, K. K., Günther, S., Sippl, W., & NtiēKang, F. (2020). Pharmacoinformatic investigation of medicinal plants from East Africa. *Molecular informatics*, 39(11), 2000163.

Udo M. D, Eyoh G. D, Jimmy C. P, Ekpo U. E. Nutrient Composition, Mineral and Anti-Nutrient Components of Processed Wild Cocoyam (*Caladium bicolor*, (Ait) Vent). *Curr Agri Res* 2020; 8(2). doi : <http://dx.doi.org/10.12944/CARJ.8.2.09>

United Nations High Commission for Refugees UNHCR 2020. SOCIOECONOMIC impact assessment of COVID-19 PANDEMIC among persons of concern in Nigeria. July 2020 UNHCR\_NGA\_2020\_SEA\_COVID19\_DDI\_v1.0

Van Wyk, B. E., & Wink, M. (2018). *Medicinal plants of the world*. CABI.

Wilkins, H. F. (2019). *Caladium*× *hortulanum*. In *CRC Handbook of Flowering* (pp. 101-104). CRC Press.

UNDER PEER REVIEW