

**Early Detection of White Matter Changes with Cognitive Decline in Parkinson's Patients**

**Abstract**

**Objective:**

The aim of this study was to detect changes in white matter in patients with Parkinson's disease applied by diffusion tensor imaging to predict cognitive impairment.

**Methods:**

Montreal cognitive assessment was applied to 50 Parkinson's disease patients to confirm cognitive decline (M: F = 41:9; age: 62.72±9.07 years) and to 20 Parkinson's disease patients with no cognitive impairment as a control (M: F =13:7; age 58.95±11.22). All patients underwent disease severity testing by using Modified Hoehn and Yahr Scale, Unified Parkinson disease rating scale and Diffusion tensor imaging (DTI) for the corpus callosum and cingulum including their involved parts to define affected tracts.

**Results:**

In PD with cognitive impairment subjects, the cognitive affection correlated with abnormal DTI parameters of the corpus callosum and cingulum. There were FA or MD differences in both the corpus callosum and cingulum pathways. These findings were independent of age, sex and total white matter volume.

**Conclusion:**

Patients with Parkinson's disease associated with cognition decline are detected by tractography changes of the corpus callosum and cingulum.

## **Keywords**

Parkinson's, Dementia, Tractography, Degenerative, White-matter.

## **Abbreviations**

DTI	Diffusion tensor imaging
FA	Fractional anisotropy
MD	Mean diffusivity
MMSE	Mini-Mental State Examination
MOCA	Montreal Cognitive Assessment
PD	Parkinson's disease
PDD	Parkinson's disease dementia
UPDRS	Unified Parkinson disease rating scale
MUH	Mansoura University Hospital
PD-NC	Parkinson's disease normal cognition

## **Introduction**

Parkinson's disease defined as a neurodegenerative disorder diagnosed by cardinal manifestations, including tremor, rigidity, bradykinesia, and postural instability. Cognitive dysfunction is a common non-motor manifestation in PD. There were six-fold increased risk for developing cognitive impairment accompanies PD Patients with older age those with age above 60 years at disease onset, increased severity and long duration of the disease are risk factors for development of dementia in PD. Parkinson's disease dementia is usually subcortical with altered personality, psychomotor retardation, and memory problems. (1)

Executive dysfunction is one of the most common cognitive impairment reported in PD. It is considered as an early signs of cognitive dysfunction that involves the prefrontal cortex of the brain and the dopamine system. White matter changes represent degeneration of axons and myelin damage, and white matter degeneration is increasingly recognized in patients with PD (2)

DTI as a novel functional MRI sequence has been applied in PD to understand the mechanisms of various clinical manifestations, it is valuable for assessing the clinical severity based on an investigation of the correlation between FA in the corpus callosum and cognitive dysfunction .DTI provides promising biomarkers for the clinical manifestations of PD (3)

The main objectives of our study were to evaluate cognitive dysfunction in a selected group of PD patients and correlated it with DTI parameters of corpus callosum and cingulum through evaluation of the role of demographic, socioeconomic, co-existing conditions, disease severity, and stage of disease progression.

### **Patients and methods**

This is a case control study approved by the Ethical Committee of faculty of medicine, Mansoura University, conducted on 70 individuals; 50 patients diagnosed as Parkinson's disease with cognitive impairment according to UK Parkinson Disease Society Brain Bank clinical diagnostic criteria and 20 Parkinson's disease patients with normal cognition as a control.

Patients and controls were selected from the Movement Disorders Clinic at the Mansoura University Hospital (MUH). Parkinson's disease patients were consecutively recruited like controls. All patients and control underwent cognitive testing using the Mini-Mental Status Examination (MMSE) and Montreal cognitive assessment a quantitative measurement of multiple domains of cognition. Disease severity was assessed using the Unified Parkinson disease rating scale (UPDRS), Modified Hoehn and Yahr Scale.

The followings were excluded from our study; Parkinson disease patients with history of repeated strokes, repeated head injury, definite encephalitis, neuroleptic treatment at onset of symptoms, supranuclear gaze palsy, cerebellar signs ,early severe autonomic involvement and oculogyric crises early severe dementia with disturbances of memory, language, and praxis.

Controls were PD without cognitive impairment. The controls showed no impairment in the cognitive tests, and had no history of psychiatric diseases.

Our participants underwent thorough medical and neurological history taking and examination with stress on clinical PD features, coexisting conditions, Motor manifestation of

PD patients by Unified Parkinson disease rating scale (4), Modified Hoehn and Yahr Scale (5) and Cognitive assessment by Mini-Mental State Examination(MMSE) (6,7) Montreal Cognitive Assessment (MOCA) (Arabic version) (8). None contrast conventional MR 3 Tesla scanner, examination including T1WI, T2WI, and FLAIR in axial, sagittal and coronal planes to exclude any structural lesions.

Diffusion Tensor imaging with fiber tracking (Tractography). Two methods of determining regional FA and MD in specific tracts are manual region of interest (ROI) analysis and tractography. Region of interest analysis enables the measurement of FA and MD at predefined locations on particular slices of a magnetic resonance image. Regions of interest (ROIs) were manually placed over corpus callosum, 3 regions of corpus callosum were evaluated (genu, body and splenium). And cingulum tractography : The cingulum was divided into two regions bilaterally Fiber tracts were required to traverse the most distal points of each segment as well as a point located midway. Left and right tracts were analyzed separately and values were averaged over the defined area of interest.

Basic activity of daily living BADL was used for assessing ADL while the brief mood introspection scale BMIS was used for assessing Behavior and mood. SPSS version 21 software was used for statistical analysis SPSS version 21.

## **Results**

The age of the studied groups ranged from 52 to 76 years in patients with PD with cognitive impairment and from 53 to 65 years in control group. Meanwhile, there is younger age ranges in control group but with no statistically significant differences ( $P= 0.147$ ). Out of the studied 50 patients with PD with cognitive impairment, 41 patients were males (82%). As regard the control groups; there were 13 males (65%).

**Table1:-** disease severity and cognitive assessment among studied subjects.

Variables	Cases group (n=50)	Control group (n=20)	Test of significance	p-value
<b>Modified Hoehn &amp; Yahr stage</b>	2.53±0.49	1.80±0.48	t=5.53	<0.001*
<b>1</b>	1 (2%)	5 (25%)		
<b>2</b>	17 (34%)	13 (65%)		
<b>2.5</b>	9 (18%)	2 (10%)		
<b>3</b>	23 (46%)	0 (0%)	MC	<0.001*
<b>Unified Parkinson disease rating scale</b>				
Mentation, Behavior and Mood	9.24±3.05	7.65±1.42	2.23	0.029*
Activities of Daily Living	21.72±6.15	20.95±5.69	0.483	0.631
Motor Examination	28.96±4.68	24.30±3.11	4.09	<0.001*
<b>Mini-Mental state examination</b>	22.28±1.67	29.70±0.65	t=11.39	<0.001*
Montreal cognitive assessment	15.88±4.42	29.55±0.68	t=13.71	<0.001*

MC: Monte Carlo test

There were significantly lower MMSE and Montreal cognitive scores in the case than in the control (**P<0.001**). The severity of PD measured by Modified Hoehn & Yahr was significantly higher in case than control (**P<0.001**). In Unified Parkinson disease rating scale, although there was significant increase in Mentation, Behavior and Mood score as well as motor examination score in case than control (**P=0.029**), (**P<0.001**) respectively, there was no significant difference of Activities of Daily Living score between the two groups (**P=0.631**).

Table 2:- Tractography derived DTI parameters for three regions of the corpus callosum and two regions of the cingulum among the studied groups \*

Variables	Cases group (n=50)	Control group (n=20)	t-test	p-value
FA	0.368±0.05	0.805±0.13	19.62	<0.001*
MD	1.07±0.23	0.400±0.04	12.91	<0.001*
<b>Number of fibers</b>	26774.4±5227	27446.6±9338	0.383	0.703
<b>Corpus callosum region of interest (ROI)</b>				
<b>Genu</b>				
<b>Genu FA</b>	0.534±0.20	0.974±0.32	6.83	<0.001*
<b>Genu MD</b>	0.861±0.12	0.580±0.16	7.98	<0.001*
<b>Body</b>				
<b>Body FA</b>	0.502±0.14	0.992±0.32	8.78	<0.001*
<b>Body MD</b>	0.925±0.16	0.613±0.12	7.67	<0.001*
<b>Spelinum</b>				
<b>Spelinum FA</b>	0.578±0.161	0.875±0.09	7.72	<0.001*

<b>Spelinum MD</b>	0.915±0.09	0.669±0.12	8.90	<0.001*
<b>Cingulum</b>				
<b>left anterior</b>				
<b>FA</b>	0.457±0.09	0.877±0.14	14.49	<0.001*
<b>MD</b>	0.867±0.11	0.524±0.12	11.07	<0.001*
<b>Right anterior</b>				
<b>FA</b>	0.420±0.09	0.938±0.22	13.70	<0.001*
<b>MD</b>	0.859±0.13	0.447±0.13	11.94	<0.001*
<b>left posterior</b>				
<b>FA</b>	0.507±0.18	0.784±0.08	6.53	<0.001*
<b>MD</b>	0.791±0.08	0.528±0.07	11.84	<0.001*
<b>Right posterior</b>				
<b>FA</b>	0.515±0.11	0.871±0.12	11.85	<0.001*
<b>MD</b>	0.810±0.07	0.476±0.13	13.69	<0.001*

Among the two studied groups FA of corpus callosum was decreased in cases than controls so, MD was higher in cases as it showed statistical significant difference ( $p < 0.001$ ). Moreover, there is no statistical significant difference between cases and control as regard number of fibers of corpus callosum ( $p=0.703$ ). In addition, There is decreased of FA and increased of MD of anterior and posterior part of cingulum in both side in comparison between case and control groups which had statistically significant difference ( $p < 0.001$ ) (Fig 1).

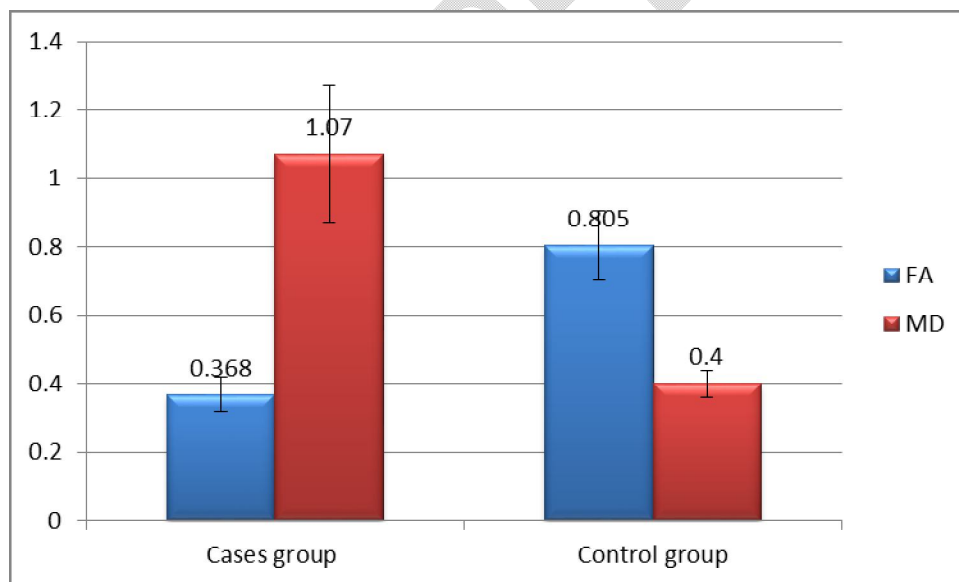


Figure (1): FA and MD among cases and control groups

Table (3): Correlation between Modified Hoehn & Yahr stage, Montreal cognitive assessment and other variables in cases group

Variables	Modified Hoehn & Yahr stage		Montreal cognitive assessment	
	R	p	R	p
Disease duration / m	0.832	<0.001*	0.139	0.335
FA	0.022	0.879	0.159	0.276
MD	-0.072	0.619	-0.153	0.290
Number of fibers	0.290	0.350	-0.134	0.352
Genu FA	-0.079	0.587	0.645	<0.001*
Genu MD	-0.145	0.315	-0.610	<0.001*
Body FA	0.124	0.392	0.677	<0.001*
Body MD	-0.110	0.448	-0.628	<0.001*
Spelinum FA	-0.045	0.759	0.091	0.531
Spelinum MD	0.159	0.269	-0.115	0.427
Left body FA	-0.310	0.028*	0.081	0.575
Left body MD	0.050	0.730	-0.052	0.721
Right body FA	0.144	0.319	0.001	0.999
Right body MD	-0.121	0.402	-0.269	0.059
Left posterior FA	-0.084	0.563	0.639	<0.001*
Left posterior MD	0.086	0.554	-0.694	<0.001*
Right posterior FA	0.024	0.868	0.221	0.123
Right posterior MD	-0.086	0.553	-0.014	0.924

There was high significant positive correlation between modified Hoehn & Yahr stage, and the duration of Disease in cases group ( $p < 0.001$ ). Also, there was significant positive correlation between the Montreal cognitive assessment and FA of Genu and body of corpus callosum ( $p < 0.001^*$ ) (Fig 2). Montreal cognitive assessment had significant positive correlation with FA of posterior part of Left cingulum ( $p < 0.001^*$ ) and inverse correlation between the Montreal cognitive assessment with MD of posterior part of Left cingulum, Genu and body of corpus callosum ( $p < 0.001^*$ ) (Fig 3). Also, there was statistical significant inverse correlation between the Modified Hoehn & Yahr stage and FA of Left body of cingulum ( $r = -0.310$ ,  $p = 0.028^*$ ).

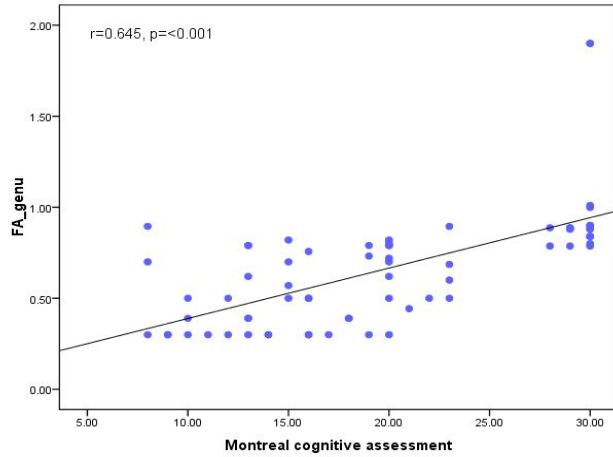


Figure (2): Scatter diagram for positive correlation between Montreal cognitive assessment and Genu FA.

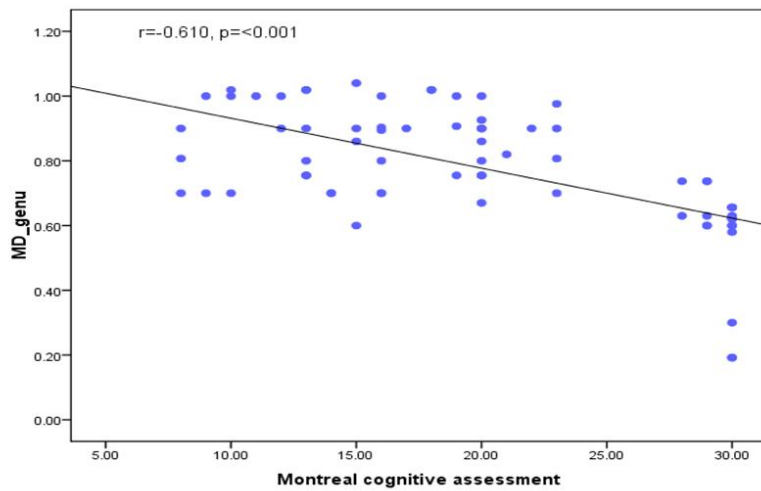


Figure (3): Scatter diagram for negative correlation between Montreal cognitive assessment and Genu MD

Table (4): Correlation between Unified parkinson disease rating scale and other variables in cases group

Variables	Mentation, Behavior and Mood		Activities of Daily Living		Motor examination	
	R	P	r	p	r	p
FA	-0.015	0.921	-0.099	0.501	-0.110	0.453
MD	0.360	0.010*	0.309	0.029*	0.218	0.127
Number of fibers	-0.073	0.615	-0.250	0.080	-0.002	0.987
Genu FA	-0.092	0.528	0.033	0.824	0.003	0.983
Genu MD	0.087	0.546	0.061	0.675	0.042	0.772
Body FA	-0.080	0.579	-0.159	0.269	-0.012	0.934

<b>Body MD</b>	<b>0.123</b>	<b>0.393</b>	<b>0.525</b>	<b>&lt;0.001*</b>	<b>0.102</b>	<b>0.479</b>
<b>Spelinum FA</b>	<b>0.075</b>	<b>0.603</b>	<b>0.253</b>	<b>0.076</b>	<b>0.091</b>	<b>0.529</b>
<b>Spelinum MD</b>	<b>0.010</b>	<b>0.947</b>	<b>-0.274</b>	<b>0.054</b>	<b>-0.180</b>	<b>0.212</b>
<b>Left body FA</b>	<b>-0.053</b>	<b>0.713</b>	<b>-0.018</b>	<b>0.901</b>	<b>-0.142</b>	<b>0.326</b>
<b>Left body MD</b>	<b>0.198</b>	<b>0.167</b>	<b>0.024</b>	<b>0.870</b>	<b>0.127</b>	<b>0.380</b>
<b>Right body FA</b>	<b>-0.004</b>	<b>0.978</b>	<b>-0.010</b>	<b>0.942</b>	<b>0.070</b>	<b>0.629</b>
<b>Right body MD</b>	<b>0.050</b>	<b>0.732</b>	<b>-0.041</b>	<b>0.780</b>	<b>0.068</b>	<b>0.640</b>
<b>Left posterior FA</b>	<b>-0.157</b>	<b>0.277</b>	<b>-0.143</b>	<b>0.323</b>	<b>-0.115</b>	<b>0.425</b>
<b>Left posterior MD</b>	<b>0.306</b>	<b>0.031*</b>	<b>0.143</b>	<b>0.322</b>	<b>0.147</b>	<b>0.307</b>
<b>Right posterior FA</b>	<b>-0.249</b>	<b>0.081</b>	<b>-0.080</b>	<b>0.580</b>	<b>-0.143</b>	<b>0.323</b>
<b>Right posterior MD</b>	<b>0.105</b>	<b>0.469</b>	<b>0.044</b>	<b>0.761</b>	<b>-0.074</b>	<b>0.608</b>

There was significant positive correlation between the Mentation, Behavior and Mood and MD of corpus callosum (Fig4) as well as posterior region of cingulum (Fig5) ( $P=0.010^*$ ), ( $p=0.031^*$ ) respectively. Also, there was statistical significant positive correlation between activities of Daily Living scores and MD of Body of corpus callosum ( $p<0.001$ ) (Fig 6)

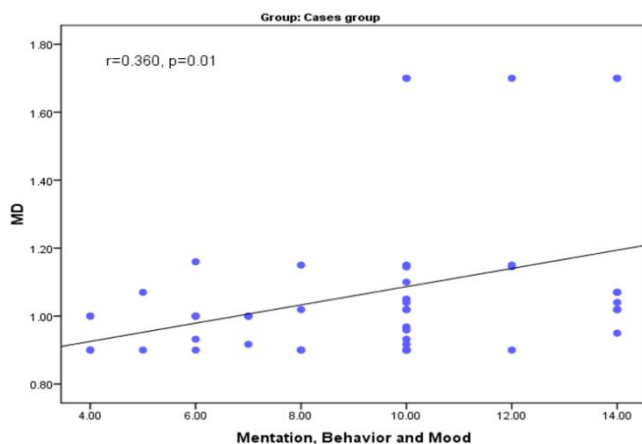


Figure (4): Scatter diagram for positive correlation between Mentation, Behavior and Mood and MD

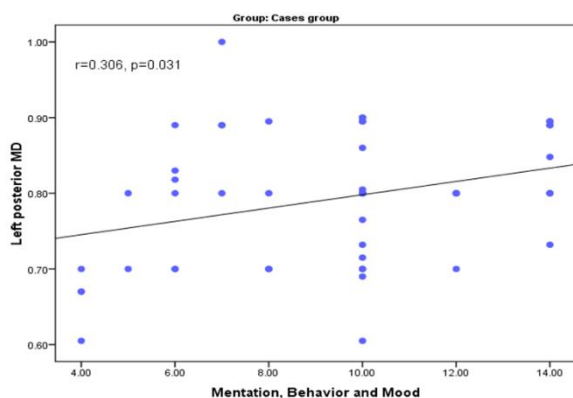


Figure (5) : Scatter diagram for positive correlation between Mentation, Behavior and Mood and Left posterior MD

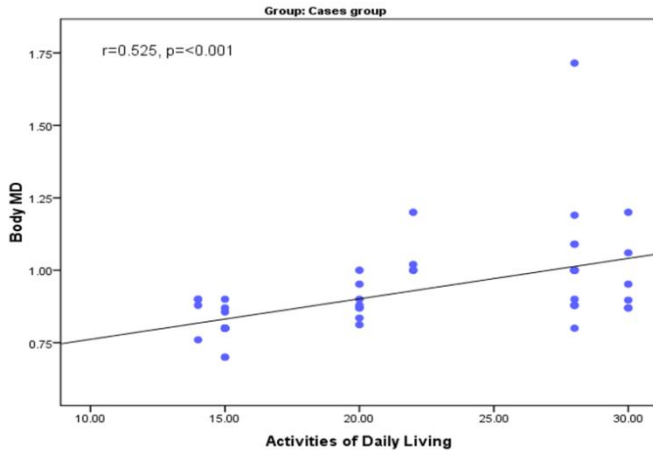


Figure (6): Scatter diagram for positive correlation between Activities of Daily Living and Body MD

Table (5): Linear regression analysis for independent predictors for Montreal cognitive assessment

Independent predictors	B	Std. Error	P - value	R2
Genu FA	-8.959	3.040	0.005*	17.1%
Genu MD	1.301	5.039	0.797	-
Body FA	-10.160	4.603	0.032*	31.4%
Body MD	-1.438	4.048	0.724	-
Left posterior cingulum FA	-8.113	3.454	0.023*	32.6%
Left posterior cingulum MD	-1.575	7.099	0.825	-

After linear regression analysis and adjusting confounding factors the following were independent predictors for cognitive impairment in PD; Genu FA (R2=17.1%), Body FA (R2=31.4%) and Left posterior cingulum FA (R2=32.6%).

## **Discussion**

Diffusion Tensor Imaging (DTI) is a novel functional MRI technique that can measure the thermal motion of water molecules. Distribution is isotropic when water molecules move in all directions randomly and there is no structure that inhibits their free motion (9).

Our study demonstrated that PD patients experience cognitive impairment, manifested by significant low scores on MOCA (15.88±4.42) than controls (29.55±0.68) (p<0.001). That comes

in agreement with (10) who conducted a study about the findings concerning the typical cognitive deficits associated with PD.

Tractography derived DTI parameters for corpus callosum and cingulum in our study showed that Cases had statistical significant decreased FA and increased MD of corpus callosum in comparison to control ( $p < 0.001$ ). However, there is no statistical significant difference between cases and control as regard number of fibers of corpus callosum ( $p=0.703$ ). Also, there is decreased FA and increased MD of anterior and posterior part of cingulum in both side in comparison between case and control groups which had statistically significant difference ( $p < 0.001$ ). This can be explained by white matter microstructural changes that may not be severe in early stages of dementia.

*Thais and colleagues 2018 (11)* who conducted his study on 120 newly diagnosed patients with early stage Parkinson's disease (27 with mild cognitive impairment PD-MCI and 93 with normal cognition PD-NC) along with 48 controls agreed with us regarding significant changes in both DTI parameters, FA decreasing and MD increasing significantly. However, compared to PD-NC, the PD-MCI group showed significant MD changes. Patients with PD-MCI had significant lower FA than controls in posterior aspect of cingula ( $p < 0.05$ ). However, Katie's study revealed no difference between PD and PDD regarding FA and MD of corpus callosum and cingulum (12)

*Katie et al., (2017)(12)* agreed with us regarding Tractography of the corpus callosum that revealed correlations of MD values in all regions of the corpus callosum ( $p < 0.05$ ), by using manual region of interest (ROI) analysis of determining regional FA and MD in specific tracts, namely the two anterior and the posterior regions of the corpus callosum.

This study revealed significant positive correlation between UPDRS part I, II with MD of corpus callosum ( $P=0.01$ ), ( $P = 0.029$ ) respectively. Also showed significant positive correlation between part I and MD of posterior region of cingulum ( $p=0.031$ ), where part II showed statistical significant positive correlation with MD of Body of corpus callosum ( $p < 0.001$ ). This is comes in agreement with (12) (*Katie et al., 2017*) Parkinson's disease and PDD groups had significantly higher UPDRS scores than controls ( $p < 0.05$ ). (*Rebecca et al., 2013*) also agreed with that result as he conducted his study on twenty five patients with PD

(fourteen males, eleven females) and twenty six healthy controls (thirteen males, thirteen females) , his study showed that the UPDRS total motor score correlated positively with MD in white-matter underlying the corpus callosum ( $p < 0.01$ ) (14). These findings suggest that PD is associated with widespread microstructural degradation and that DTI may have value as an imaging marker for PD. other studies proved The correlations between nigral dopaminergic neuronal degeneration and PD severity as characterized by total UPDRS scores have been observed in PET(15,16)and SPECT(17,18) studies.

Our study showed statistical significant positive correlation between the Montreal cognitive assessment and FA of corpus callosum and cingulum ( $p < 0.001$ ). And significant statistical inverse correlation with MD of Left posterior part of cingulum ( $p < 0.001$ ) and MD of Genu and body of corpus callosum ( $p < 0.001$ ). *Kamagata et al., (2013)*, conducted a study which revealed significant changes in MD (increase) and FA (decrease) in the corpus callosum. It has been shown that the deterioration of the corpus callosum genu is linked to PD dementia as well as executive and attention dysfunctions (19), (20).

Limitations of our study include lack of postmortem diagnosis. A side from diagnostic uncertainty, it is possible that some patients diagnosed with PD also had other comorbid neurological conditions that may have skewed the outcome of this study. The sample size is relatively low, and thus power issues make it difficult to reach statistical significance. Not all patients with PD had measurable cognitive impairment. Thus, it is possible that more pronounced changes and stronger associations with cognition would have been detected if we had focused on patients with PD with established MCI. Only FA and MD mean diffusivity were evaluated, whereas other parameters, such as radial diffusivity, axial diffusivity, were not explored.

### **Conclusion**

PD patients with cognitive impairment achieve lower scores on MMSE and MOCA. Cognitive dysfunction in Parkinson disease patients (PD) includes executive dysfunction, visuo-perceptual / visuospatial tasks and impairments in both immediate and delayed story recall. Using DTI tractography in patients with PD or PDD to determine if subtle pathologic changes are present in

these white matter tracts. Tractography of corpus callosum and both cingulua revealed significant decreased FA and increased in MD in case than control group.

#### **Consent and Ethical Approval:**

As per international standard or university standard guideline participant consent and ethical approval has been collected and preserved by the authors.

#### **References**

1. Nicolaas I, Bohnen and Roger L. Albin. (2013). White matter lesions in Parkinson disease. *Nat Rev Neurol*. 2011 Apr; 7(4): 229–236.
2. Laura J.de, Mark J.R.J.Bouts, Jeroenvan der Grond et al. (2019). Age- and disease-related cerebral white matter changes in patients with Parkinson's disease. *Neurobiology of Aging*. Volume 80, August, Pages 203-209.
3. Lenfeldt N, Hansson W, Larsson A, Nyberg L, Birgander R, Forsgren L. (2013) Diffusion tensor imaging and correlations to Parkinson rating scales. *J Neurol* 2013;260:2823-2830.
4. Barona, M., Brown, M., Clark, C., Frangou, S., White, T., and Micali, N. (2019). White matter alterations in anorexia nervosa: evidence from a voxel-based meta-analysis. *Neurosci. Biobehav. Rev.* 100, 285–295.
5. I. Altmann-Schneider, J. Van Der Grond, P.E. Slagboom, R.G. Westendorp, et al. (2013). Lower susceptibility to cerebral small vessel disease in human familial longevity: the Leiden longevity study. *Stroke*, 44, pp. 9-14.
6. Folstein, M.F., Folstein, S.E. and McHugh, P.R. (1975). Mini Mental State, a practical method for grading the cognitive state of patients for the clinician. *J. Psychiatr. Res.* 12, 189±98

7. J.L.R. Andersson, S.N. Sotiropoulos. (2016). An integrated approach to correction for off-resonance effects and subject movement in diffusion MR imaging *Neuroimage*, 15, pp. 1063-1078.
8. C. Atkinson-Clement, S. Pinto, A. Eusebio, O. Coulon. (2017). Diffusion tensor imaging in Parkinson's disease: review and meta-analysis *Neuroimage Clin.*, 15, pp. 98-110.
9. Yu, Z., Tao, L., Qian, Z., et al. (2016). Altered brain anatomical networks and disturbed connection density in brain tumor patients revealed by diffusion tensor tractography. *Int. J. Comput. Assist. Radiol. Surg.* 11 (11), 2007–201.
10. Guan, X., Huang, P., Zeng, Q., Liu, C., Wei, H., Xuan, M., et al. (2019). Quantitative susceptibility mapping as a biomarker for evaluating white matter alterations in Parkinson's disease. *Brain Imaging Behav.* 13, 220–231.
11. Thais Minett . Li Su . Elijah Mak, et al. (2018). Longitudinal diffusion tensor imaging changes in early Parkinson's disease: ICICLE-PD
12. Katie Wiltshire, Luis Concha ,Myrlene Gee ,Thomas Bouchard, Christian Beaulieu ,Richard Camicioli. (2015) Corpus Callosum and Cingulum Tractography in Parkinson's Disease *The Canadian journal of neurological science. Le journal canadien des sciences neurologiques* · September.
13. J.W. Chung, R.G. Burciu, E. Ofori, P. Shukla, M.S. Okun, C.W. Hess, D.E. Vaillancourt. (2017). Parkinson's disease diffusion MRI is not affected by acute antiparkinsonian medication *Neuroimage Clin.*, 14, pp. 417-421.
14. Rebecca J.Theilmann, Jason D. Reed, David D. Song, Mingxiong X. Huang, Roland R. Lee, Irene Litvan and Deborah L. Harrington.(2013). White-matter changes correlate with cognitive functioning in Parkinson's disease DOI: 10.3389/fneur.2013.00037 · Source: PubMed.
15. Wei X, Luo C, Li Q, Hu N, Xiao Y, Liu N, Lui S and Gong Q. (2021). White Matter Abnormalities in Patients With Parkinson's Disease: A Meta-Analysis of Diffusion Tensor Imaging Using Tract-Based Spatial Statistics. *Front. Aging Neurosci.* 12:610962.

16. Inguanzo, A., Sala-Llonch, R., Segura, B., Erostarbe, H., Abos, A., Campabadal, A., et al. (2020). Hierarchical cluster analysis of multimodal imaging data identifies brain atrophy and cognitive patterns in Parkinson's disease. *ParkinsonismRelat. Disord.* 82, 16–23.
17. Albrecht, F., Ballarini, T., Neumann, J., and Schroeter, M. L. (2019). FDG-PET hypometabolism is more sensitive than MRI atrophy in Parkinson's disease: A whole-brain multimodal imaging meta-analysis. *Neuroimage. Clin.* 21:101594.
18. Aarsland, D., Andersen, K., Larsen, J. P., & Lolk, A. (2003). Prevalence and characteristics of dementia in Parkinson disease: an 8-year prospective study. *Archives of neurology*, 60(3), 387-392.
19. Kamagata K., Tomiyama H., Motoi Y., Kano M., Abe O., Ito K., Shimoji K., Suzuki M., Hori M., Nakanishi A., Kuwatsuru R., Sasai K., Aoki S., Hattori N. (2013) Diffusional kurtosis imaging of cingulate fibers in Parkinson disease: comparison with conventional diffusion tensor imaging. *Magn. Reson. Imaging.* ;31(9):1501–1506.
20. Andica, C., Kamagata, K., Hatano, T., Saito, Y., Ogaki, K., Hattori, N., et al. (2020). MR biomarkers of degenerative brain disorders derived from diffusion imaging. *J. Magnet. Reson. Imag.* 52, 1620–1636.