

PRIMARY SYSTEMIC AMYLOIDOSIS OF TONGUE: PITFALL AND CHALLENGES IN THE DIAGNOSIS.

ABSTRACT

Amyloidosis is caused by deposition of insoluble fibrillary protein in tissues and organs resulting in severe organ dysfunction. The clinical presentation for the diagnosis of amyloidosis is nonspecific, making it one of the most underdiagnosed conditions. Treatment is now available and is effective in improving patient's survival and quality of life. We present a case of generalized amyloidosis in a 71-year-old patient admitted with a diagnosis of benign neoplasm of the root of the tongue. Subsequently, she underwent surgical treatment followed which, purulent-septic complications developed leading to death. Microscopic examination of the biopsy tissue revealed deposits of amyloid and the patient was diagnosed to have primary generalized amyloidosis. These facts confirm the essential need to differentiate tumors from amyloidosis. Hence, the aim of this paper is to provide physicians with knowledge about the clinical presentation that raise the suspicion of amyloidosis, bearing in mind the importance of early diagnosis.

Keywords: amyloidosis; macroglossia; benign neoplasms

Introduction:

Amyloidosis is characterized as assembly of various conditions/diseases leading to accumulation of the amyloid protein in the tissues hence causing local or systemic damage to the organs.¹ The development of amyloid is considered among complex processes which involves vital role from the extracellular substances.^{2,3} Amyloidosis is frequently termed as "The great imitator," this is due to its nonspecific clinical presentation. The clinical features are uncommon and varying depending upon the organ that is involved. Clinically, it can be classified as: localized and systematic.⁴ Survival of patients with systemic amyloidosis is extremely heterogeneous depending on the organs involved and the presence and extent of cardiac damage. Patients with localized amyloidosis have a considerably better prognosis

than do those with systemic disease.⁵ Hence, the early diagnosis of the amyloid process would provide the highest degree of therapeutic efficacy.

Case presentation

Clinical Case: A 71 years old patient was admitted with the complaints of difficult and painful swallowing, problems in speech and difficulty in tongue movement, and a drastic weight loss. Preliminary diagnosis made was benign neoplasm (BN) of the root of the tongue. The investigations were done and an ultrasound of the neck showed submandibular lymph nodes measuring upto to 1.5 cm with signs of reactive changes. The findings on computed tomography (CT) could not be concluded as the visualization of the root of the tongue was not impossible due to artifacts emanating from metal structures in the oral cavity (dentures).

Laboratory findings:

- Complete blood count:
 - 1) hemoglobin - 154 g/l,
 - 2) erythrocytes - $4.9 \times 10^{12}/l$,
 - 3) leukocytes - $12.5 \times 10^9/l$, stab - 8%, segmented - 64%,
 - 4) lymphocytes - 21% ,
 - 5) monocytes - 6%,
 - 6) erythrocyte sedimentation rate - 19 mm/h.
- Biochemical examination of the blood:
 - 1) creatinine - 72.3 $\mu\text{mol}/l$,
 - 2) glucose - 5.1 mmol/l,
 - 3) total protein - 60.4 g/l.
- Coagulogram findings:
 - 1) prothrombin time - 19.4 s,
 - 2) thrombin time - 15.9 s,
 - 3) activated partial thromboplastin time - 24.3 s,
 - 4) amount of fibrinogen - 4.44 g/l.
- Urinalysis: no significant findings.

Treatment performed:

The patient underwent a scheduled surgery. Biopsy of the tumor of the root of the tongue was taken through the transcervical access. Based on the biopsy findings the diagnosis made was 'benign mesenchymoma' of the root of the tongue. The patient was discharged in a relatively satisfactory condition. However, after 5 days of post discharge, he was urgently admitted to the surgical department in a serious condition. Despite the treatment, the patient's condition deteriorated rapidly and he went into the respiratory failure and was declared dead and an autopsy was performed.

The results of the autopsy showed that the tongue was significantly thickened in the region of the root to the extent that it was difficult for the little finger to pass into the throat. It was noted that the muscle of the tongue had yellow foci which was firm to touch and were present throughout the root of the tongue.

Microscopic examination of the autopsy tissue showed the following findings:

➤ **Biopsy from the root of the tongue:**

- interstitial edema and diffuse homogeneous deposits of weakly eosinophilic (Fig. 1, a), congophilic (Fig. 1, b), with birefringence (Fig. 1, c)

➤ **Biopsy from the lung:**

- dystelectasis with vessel walls having an uneven thickness due to the deposition of a homogeneous eosinophilic and congophilic protein substrate and endovasculitis. Deposition of a homogeneous eosinophilic protein substrate (amyloid angiopathy) with scattered leukocyte infiltration and alveolar edema. (Fig. 1, d).

➤ **Biopsy from the myocardium, liver, spleen, kidney and bone marrow:**

- presence of amyloid angiopathy of varying severity (Fig. 1, e-g).

Based on the biopsy reports the diagnosis of primary generalized amyloidosis was made. The clinical symptoms were masked due to damage to the respiratory system. The presence of diffuse infiltration of amyloid resulted in a mass of the soft tissues of the tongue simulating tumor growth. This is a rare case as due to masking effect of artifacts that found on CT. Death occurred due to infectious complications leading to multiple organ dysfunction.

Discussion

Diagnosis of systemic amyloidosis is challenging due to its non-specific presentation along with wide range of manifestation. The signs and symptoms of AL amyloidosis includes

macroglossia, loss of appetite, dyspnea, bruising around the eye, nephrotic syndrome, unexplained heart failure, peripheral neuropathy, carpal tunnel syndrome and nephrotic syndrome. Amyloidosis of the oral cavity is less frequent; tongue amyloidosis is a rare presentation of localized amyloidosis compared to systemic amyloidosis which is common.⁶

The most accurate method for determining the type of amyloid is immunohistochemical analysis for amyloid precursor proteins, but it is currently not widely available.²

Differential diagnosis of systemic amyloidosis affecting tongue region includes infectious diseases caused by organisms such as herpes simplex virus, syphilis, and coxsackie virus. Hence, the history and physical signs showing any type of rash or presence of history of fever and exposure to virus is very important. Also, oral cancers, especially metastatic are to be considered. Metabolic disorders such as scurvy and iron deficiency anemia may cause tongue abrasion and generalized malaise and hence can be kept in the differential diagnosis.^{7,8}

Delayed diagnosis is unfortunately common in amyloidosis. A published data represented significant delay in the diagnosis of amyloidosis, with a median time taken for the diagnosis to be 7 months. 37% of participants reported a delayed diagnosis of over a year since symptoms begin and over 10% cases were diagnosed after more than 3 years after clinical presentation.⁹ The prognosis of systemic amyloidosis is seen to be poor, the earlier the diagnosis the more effective and efficiently the therapy can help.¹⁰

Current recommendations regarding amyloidosis:

- Diagnosis of amyloidosis should be suspected in cases of diffuse or localized swelling of tongue
- Congo red stain is currently the gold standard for amyloid detection
- The type of amyloid must be identified microscopically or immunohistochemically to help to do clinical evaluation and treatment.
- Mass spectrometry can be performed to in cases where amyloid can't be characterized.

REFERENCES

1. Cowan AJ, Skinner M, Berk JL, et al. Macroglossia - not always AL amyloidosis. *Amyloid*. 2011;18(2):83-86
2. Merlini G. AL amyloidosis: from molecular mechanisms to targeted therapies. *Hematology Am Soc Hematol Educ Program*. 2017;2017(1):1-12.
3. Yakupova EI, Bobyleva LG, Shumeyko SA, Vikhlyantsev IM, Bobylev AG. Amyloids: The History of Toxicity and Functionality. *Biology (Basel)*. 2021;10(5):394
4. Vaxman I, Dispenzieri A, Muchtar E, Gertz M. New developments in diagnosis, risk assessment and management in systemic amyloidosis. *Blood Rev*. 2020;40:100636.
5. Absmeier RM, Rottenaicher GJ, Svilenov HL, Kazman P, Buchner J. Antibodies gone bad - the molecular mechanism of light chain amyloidosis. *FEBS J*. 2022;10.1111/febs.16390.
6. Liakou CI, Koh J, Tsimpidakis A, Rios K, Paskalis C, Pipilis A, Kantianis D, Georgiadis T, Razis E. A Tongue Lesion as a Sign of a Systemic Disease. *Case Rep Med*. 2016;2016:6723575.
7. Mortazavi H, Safi Y, Baharvand M, Rahmani S. Diagnostic Features of Common Oral Ulcerative Lesions: An Updated Decision Tree. *Int J Dent*. 2016;2016:7278925.
8. Bahgat A, Vicini C. Postoperative amyloidosis of tongue base: Extremely rare complication after multilevel sleep surgery. *Clin Case Rep*. 2021;9(3):1504-1506.
9. Lousada I, Comenzo RL, Landau H, Guthrie S, Merlini G. Light Chain Amyloidosis: Patient Experience Survey from the Amyloidosis Research Consortium. *Adv Ther*. 2015;32(10):920-8
10. Gertz MA, Dispenzieri A. Systemic Amyloidosis Recognition, Prognosis, and Therapy: A Systematic Review. *JAMA*. 2020;324(1):79-89.

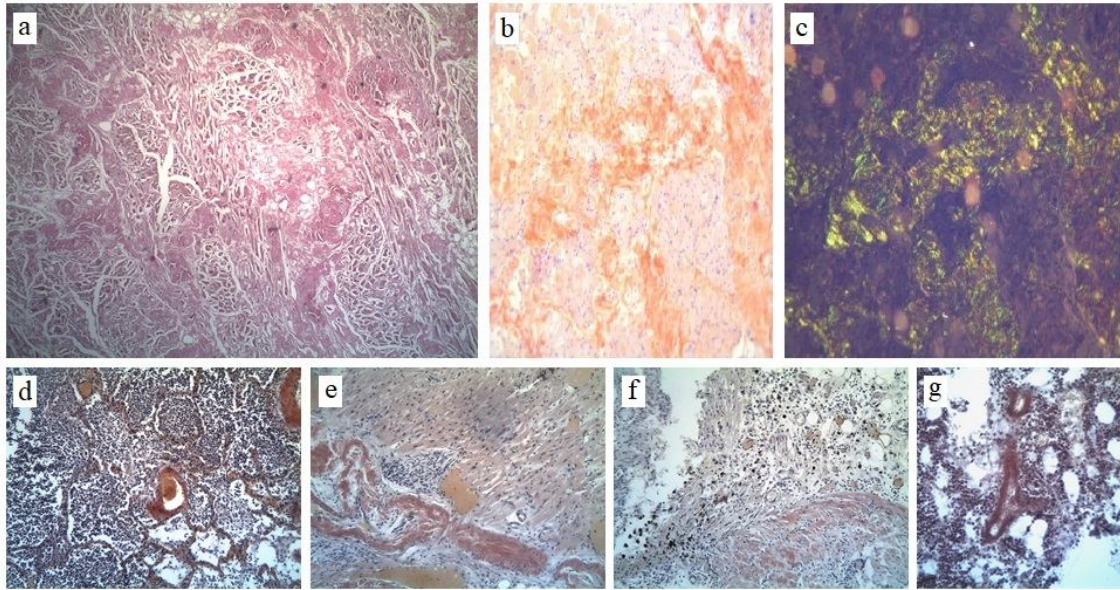


Fig. 1. Primary generalized AL-amyloidosis:

a - amyloid tumor of the root of the tongue (macroglossia), amyloid deposits in the intermuscular spaces and in the walls of blood vessels. Stained with hematoxylin and eosin, x100;

b - amyloid deposits in the root of the tongue (macroglossia). Coloring with alkaline Congo red, x200;

c - amyloid deposits in the root of the tongue (macroglossia). Stained with alkaline Congo red with a study in polarized light, x200;

d - focal pneumonia with amyloid deposits in the interalveolar septa with amyloid angiopathy. Alkaline Congo red stained with hematoxylin and eosin, x100;

e - amyloid in the intramural myocardial artery (amyloid angiopathy). Alkaline Congo red stained with hematoxylin and eosin, x200;

f - amyloid deposits in the tissues of the pelvis and calyces of the kidney. Alkaline Congo red stained with hematoxylin and eosin, x200;

g - amyloid angiopathy in the bone marrow. Alkaline Congo red stained with hematoxylin and eosin, x100.