

A short overview of Cervical spondylosis, including its diagnosis and current treatment strategies

ABSTRACT

The intervertebral discs, which normally break, lose water content, and collapse with ageing, are the cause of cervical spondylosis. Overall, 99.7% of people responded, with 99.6% of males and 99.8% of women doing so. 1820 men (47.27%) and 2029 women (52.73%) outnumbered each other equally among the participants. The typical age was 45, 85, 16, and 19 years old. The medical management of cervical spondylosis includes neck immobilization, drug therapy, dietary modifications, and physical therapies such as traction, manipulation, exercises, and heat therapy. Since there haven't been any comprehensive studies comparing different modalities, these treatments are typically initiated based on the clinician's preferences or areas of competence. Comparing the effectiveness of various therapy techniques against that of no treatment at all is difficult and riddled with ethical problems. The most frequent symptoms are cervical pain, radiculopathy, or myelopathy. Cervical pain is predominantly transmitted by the posterior ramus branch and sinuvertebral nerve. Radiculopathy is brought on by nerve root compression. These comprise the sensory, motor, and autonomic systems. This review article discusses the pathophysiology, aetiology, treatment, diagnosis, and risk factors for cervical spondylosis.

Keywords: Cervical spondylosis, Histopathology and Epidemiology, Causes, Pathophysiology, Diagnosis, Treatment.

INTRODUCTION

A painful disorder affecting many people, cervical spondylosis is very common. Neck discomfort, like back pain, is multi-factorial in origin, reflecting poor posture, muscle strain, sporting and occupational activity, as well as psychological aspects. It is the second most common musculoskeletal reason for consultation with an orthopaedic surgeon globally. Radiculopathy and myelopathy may be brought on by cervical spondylosis(1). The term "cervical spondylosis" refers to the narrowing of the cervical spine's neural foramina and spinal canal as a result of multifactorial degenerative processes(2). The most prevalent spinal dysfunction in elderly persons is cervical spondylosis, commonly known as cervical degenerative disease. With paraparesis and quadriparesis as a result, it is the most typical cause of nontraumatic myelopathy. Adults experience 20 to 50 per cent of cases of neck pain annually, with spondylosis being a major contributor. Cervical degenerative disease is one of the conditions that medical professionals see most frequently, along with lumbar spondylosis(3). In the adult population, 55% of workers used

screens at some point in their lives, compared to 48.5% of adults overall. Neck discomfort was one of the top 10 causes of years lived with disability, per the 2013 Global Burden of Disease study, which included 301 acute and chronic diseases and injuries in 188 countries. Comparatively, it came in at number four worldwide and number two in China. Due to the frequent use of expensive surgery as a treatment, cervical spondylosis lowers life quality and increases the financial burden. Consequently, cervical spondylosis may start to affect the well-being of the public. Finally, information was incorporated into the analysis. Overall, there were 99.7% of responses, with 99.6% of men and 99.8% of women responding. The participants were split equally across genders, with 1820 men (47.27%) and 2029 women (52.73%). 45.85 16.19 years old was the average age(4). Seven spinal bones make up the neck and run continuously from the head cranially to the thoracic vertebrae caudally. There are three crucial tasks that the cervical spine carries out. The skeletal structure that serves as the head's structural support is first provided by it. The second function of the cervical spine is to safeguard the cervical spinal cord and the nerve roots that exit the area. Finally, the cervical spine offers far more motion than the rest of the spine. The only named vertebrae are the atlas (C1) and axes (C2), which are situated most cranially(5). A variety of symptoms are brought on by degenerative alterations in the cervical spine's zygoapophyseal and amphiarthrodial joints. Cervical spondylosis or cervical osteoarthritis are two names for this condition. Many patients come to the ENT outpatient department with a variety of disease-related problems. 90% of people older than 65 are affected by it(6,7). As opposed to arthritis, which is connected to diarthrodial joints and synovial space, intervertebral disc degeneration results from osteophyte development of the amphiarthrodial joint. One of the hallmarks of spondylosis that sets it apart is the non-inflammatory disc degeneration(8). The complex process of disc degeneration includes several changes to the body's regular physiology in addition to the aging process. Mild segmental instability frequently occurs before it. 10% of people experience spondylosis by the age of 25, and 95% by the age of 65; it is a natural part of aging. Neck discomfort can be either acute or persistent, and it often occurs without a trigger event. Rather than degenerative facet alterations, degenerative discs appear to be the cause more frequently. The posterior principal ramus's branches innervate the facets(9). Cervical discomfort, radiculopathy, or myelopathy are the most common symptoms. The sinuvertebral nerve and posterior ramus branch supply primarily carry cervical discomfort. The compression of nerve roots causes radiculopathy. These include sensory, motor, and autonomic. Pain, paresthesia, or hyperesthesia are signs that the senses are involved. Pain may be felt in the neck, upper limbs, scapular area, head, and both arms up to the fingertips. In the corresponding myotome, pain can be myalgic, which is mild, or neuralgic, which is acute and shooting in character(10). Neck immobilization, pharmaceutical therapy, lifestyle changes, and physical modalities like traction, manipulation, exercises, and heat therapy are all part of the medical treatment for cervical spondylosis. Since no thoroughly conducted trials comparing various modalities have been conducted, these therapies are frequently started depending on the clinician's preference or area of expertise. It is challenging and fraught with ethical dilemmas to compare these treatment modalities' efficacy to that of no treatment at all(11,12). These days, there is a major public health problem with pain. According to the WHO estimate, 1 in 10 adult patients are diagnosed with chronic pain each year and 1 in 5 persons worldwide experience some form of pain at some point in their lives. This new public health concern, which is

detrimental to both individual health and general well-being, is also made worse by neck pain. Indirectly, treatment also comes with a significant financial burden(13).

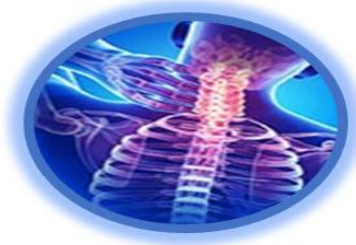


Fig.1:Cervical spondylosis.

SPONDYLITIS VS. SPONDYLOSIS: DIFFERENCES

Cervical spondylosis is one of several types of spondylosis. Localized symptoms and radiating symptoms are the two main classifications of spondylosis symptoms. A herniated disc can cause localized symptoms of spondylosis, which can include a dull ache, restricted motion, or a sense of instability. When nerves in the spine are impacted by other conditions including bulging discs and bone spurs, symptoms of spondylosis can radiate to distant parts of the body. In cases of cervical spine degeneration, symptoms such as pain, numbness, weakness, and tingling sensations might affect the shoulders and arms, whereas in cases of lumbar spine degeneration, they can affect the buttocks, thighs, legs, and feet. Ankylosing spondylitis is referred to as spondylitis and can affect practically anyone, though it tends to affect males more frequently than women. Symptoms of spondylosis typically appear after age 50. Conversely, the development of spondylitis often occurs between the ages of 20 and 40, and when it reaches an advanced stage, the spine's bones may actually fuse, making mobility uncomfortable and challenging(14).

HISTOPATHOLOGY AND EPIDEMIOLOGY

Disc herniation may be a mild form of spondylosis' early-stage precursor. Although the degenerative changes that both spondylotic discs and herniated discs experience (such as macrophage infiltration, elevation of growth factors, and cytokines) are comparable, there are immunohistological differences between the two disease processes. 500 cervical intervertebral discs removed from 198 patients with disc herniation and 166 individuals with spondylosis were investigated en bloc samples in a 2008 study by Kokubo et al. using histological examination and immunohistochemical labelling. The abundance of CD68-positive macrophages, tumour necrosis factor-alpha (TNF-alpha), matrix metalloproteinase (MMP)-3, basic fibroblast factor (bFGF), and vascular endothelial growth factor (VEGF) was found in chondrocytes from both groups. However, CD68-positive macrophage infiltration into the outer layer of the annulus fibrosus was seen in herniated discs, which showed more severe inflammatory reactions. However, it was

shown that spondylotic discs had bigger bony endplates and more widespread expression of TNF-alpha and MMP-3 in the inner layer of the annulus fibrosus(15,16).The majority of adults with spondylotic alterations of the cervical spine on radiographic imaging are asymptomatic, with degenerative changes being evident in 25% of people under the age of 40, 50% of people over the age of 40, and 85% of those over the age of 60. C6-C7 and C5-C6 are the levels that are most commonly impacted.The most typical symptom of symptomatic cervical spondylosis is neck pain. Point prevalence of neck discomfort in the general population ranges from 0.4% to 41.5%, 1-year incidence from 4.8% to 79.5%, and lifetime prevalence up to 86.8%. Low back and neck pain continues to be the fourth highest cause of disability-adjusted life years (DALYs) and the number one cause of years lived with disability (YLD), respectively, according to the Global Burden of Disease 2015 report(17–19).

CAUSES

Age-related degradation of the cervical spinal components and intervertebral discs is the main risk factor for and contributor to the incidence of cervical spondylosis. The spinal canal and intervertebral foramina widen as a result of degenerative alterations in the surrounding structures, including the facets joints, posterior longitudinal ligament (PLL), and ligamentum flavum.The three medical signs associated with cervical spondylosis are axial neck pain, cervical myelopathy, and cervical radiculopathy. These syndromes are caused by compression of the spinal cord, spinal vasculature, and nerve roots.Experiencing significant spinal trauma, having a congenitally narrow vertebral canal, having dystonic cerebral palsy that affects the cervical musculature, and participating in certain sports like rugby, soccer, and horseback riding are all risk factors that can hasten the disease process and cause early-onset cervical spondylosis(17,20).

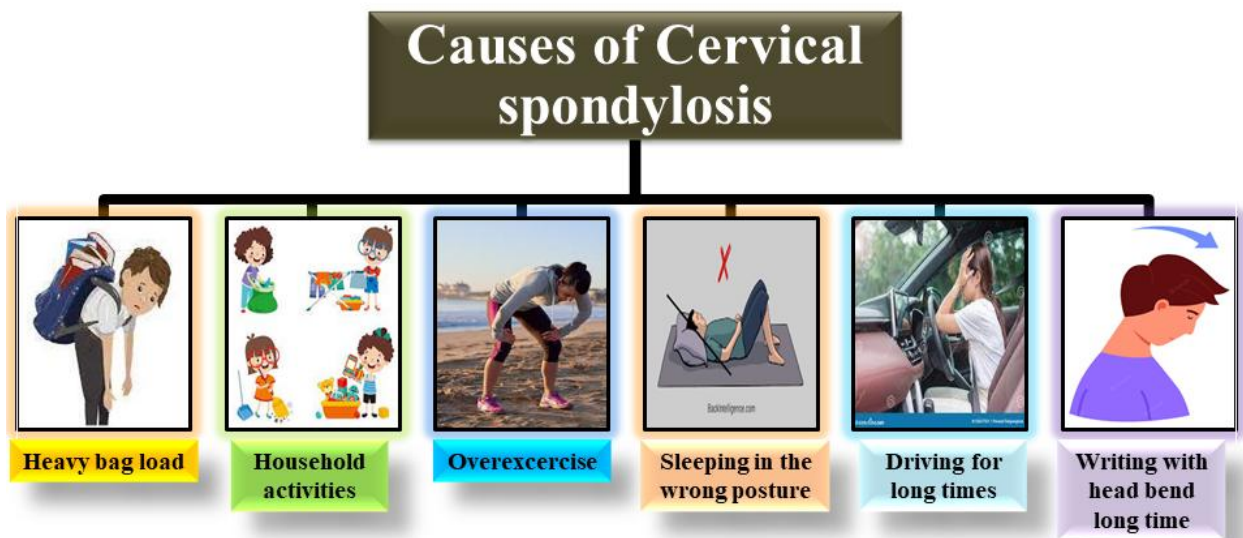


Fig.2:Cervical spondylosis's causes.

SIGNS AND SYMPTOMS

Cervical spondylosis is a degenerative condition that primarily affects persons who labour continuously while slouching. The condition is mostly brought on by ageing, but the severity of symptoms and functional impairment varies from person to person and depends on the location and rate of degradation. Cervical spondylosis risk factors include age, gender, and work. Diagnostic criteria for cervical spondylosis frequently only include clinical signs and symptoms(21,22). Signs include limited range of motion, poorly localized discomfort, and subtle neurological abnormalities. Symptoms include retro-orbital or temporal discomfort, referred pain, and cervical pain that is made worse by movement. stiffness in the neck, generalized numbness, tingling, or upper-limb weakness, nausea or vertigo, and bad balance. Syncope sporadically causes migraines(23).

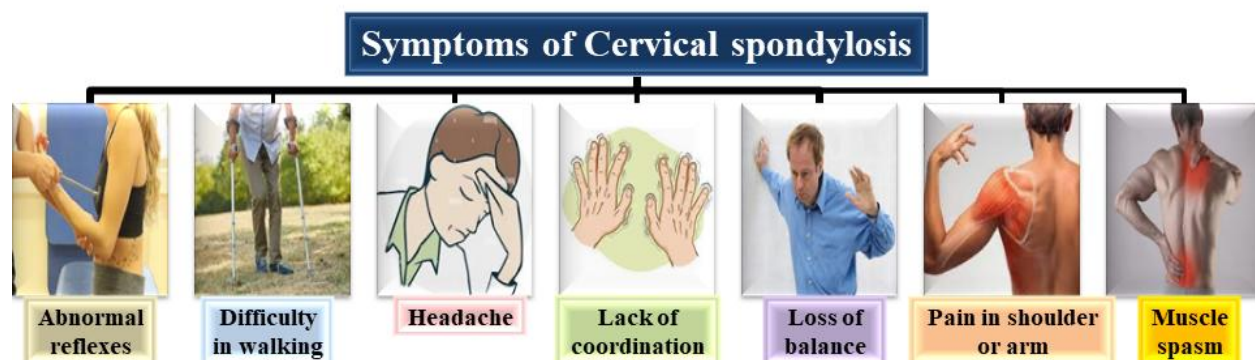


Fig.3: Some common cervical spondylosis symptoms.

RISK FACTORS

The cervical spondylosis risk factors by using MR analysis with single and multiple variables. We also looked at the effects of common risk factors for cardiovascular disease, such as smoking, body mass index, blood pressure, and low-density lipoprotein cholesterol, on cervical spondylosis. We further conducted a mediation analysis to determine the percentage of education's effect on cervical spondylosis that was mediated through taking cardiovascular risk factors for those cardiovascular risk factors for which there was MR evidence of an unfavourable effect of their genetically predicted levels on cervical spondylosis risk(24). The severity of symptoms and functional impairment varies from person to person and is dependent on the location and rate of degeneration. Cervical spondylosis risk factors include age, gender, and work(21).

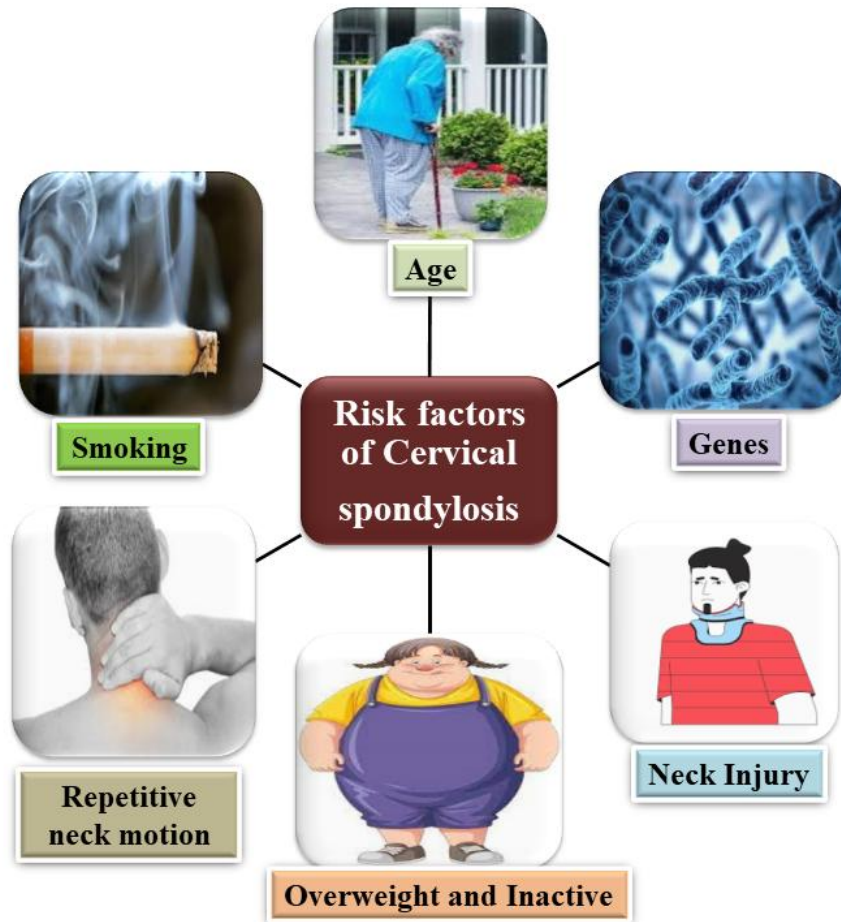


Fig.4:Cervical spondylosis risk factors.

PATHOPHYSIOLOGY

The deterioration of the intervertebral discs, which break down, lose water content, and collapse with normal aging, is what leads to cervical spondylosis. The cartilaginous end plates at the vertebral body lip experience higher mechanical stress as a result of disc degeneration. As a result, osteophytic bars or subperiosteal bone growth develops along the ventral portion of the spinal canal, occasionally encroaching on nearby nerve tissue. Osteophytes or "hard disc disease" should be distinguished from fibrocartilage soft disc herniations that affect young and middle-aged people(25–27).15%–40% of patients experience spondylosis alterations in the cervical spine at levels with a single disc space, while 60%–85% of patients experience changes at numerous levels. Most frequently, the discs between the third and seventh cervical vertebrae are impacted. Cervical spondylosis may develop as a result of repetitive occupational injuries. Dancers, gymnasts, people with spasmodic torticollis, and those who carried high weights on their heads or shoulders have all been linked to an increased frequency of this condition. The idea that trauma has a significant causal role in the development of this condition is not universally accepted. Cervical spondylosis, which affects 10% of individuals, is brought on by

congenital bone anomalies-blocked vertebrae, and deformed laminae-that put undue strain on nearby intervertebral discs(27–30).Spinal cord compression symptoms may be brought on by cervical spondylosis. A significant risk factor for spondylotic myelopathy in individuals is the presence of a congenitally small spinal canal with a diameter of 10 to 13 mm. Congenital spinal stenosis is sporadic, familial, and more common among achondroplastic dwarfs. It is also poorly understood.As a result of degenerative spinal alterations that further restrict the already narrow spinal canal, symptoms of cord compression emerge.Ventral spondylotic bars are frequently the cause of degenerative stenosis. Spinal stenosis is also brought on by the ligamentum flavum collapsing into the posterior spinal canal, laminar "shingling," and thickening of the bone and ligaments of the spinal column. The sagittal diameter of the canal may become even more limited due to pathologic vertebral body subluxations. The pathogenesis of cervical spondylotic myelopathy has been linked to other causes besides static cord compression(31).Chronic cumulative cord trauma from vertebral body pathology or spinal cord impaction on bony spurs are both caused by cervical motion. When the spinal cord is squeezed between anterior osteophytes and aposteriorly infolding ligamentum during neck extension, an acute spinal cord injury may result. It is also believed that vascular stenosis and repetitive small trauma-induced contusions to the brain might cause neural ischemia and contribute to the condition.Patients with cervical spondylotic myelopathy have flattened spinal cords where the spondylotic protrusions are located(32,33).When there is compression, the gray matter becomes ischemic, losing neurons and occasionally developing cavitory lesions. Below the level of compression, the lateral descending columns degenerate, while the ascending posterior columns degenerate above the level of compression.Necrosis, demyelination, and atypical pallor are examples of white matter lesions.Compression of the nerve root in the neural foramina results in cervical spondylotic radiculopathy(34–36).Along with radicular arteries and veins, the root typically takes up roughly a third of the foramen space. The facet joint in the back of the disc and uncovertebral joints in the front can both compress the root. The disc may rupture or calcify, the facet and uncovertebral joints may enlarge, etc. It is hypothesized that nerve root discomfort could potentially result from discal proteoglycans being broken down without being compressed directly.Spondylotic radiculopathy patients have flattened nerve roots and surrounding root sleeve fibrosis. Wallerian degeneration is not prevalent(27,37).

DIAGNOSIS OF CERVICAL SPONDYLOSIS

Following a thorough physical examination with a focus on the neck, back, and shoulders, bending tests, the strength of the hands and arms, loss of sensation, and a walking test, the doctor will typically start by asking the patients about their symptoms and medical history. The patient's head is bent laterally while being compressed downward to perform the predictive cervical compression test. Having pain in the neck or shoulders on the side to which the head is laterally bent is a good sign. Neck flexion and the Lhermitte sign both imply an electrical shock. The most common objective finding during a physical examination is reduced neck range of motion(38–41).Although they are often not conclusive, MRI and CT scans are useful for diagnosing pain and should be taken into account with physical exams and medical history. Spondylosis can cause lumbar back discomfort, but muscle strain is the most frequent cause. Imaging tests including X-rays, computed tomography (CT), and magnetic resonance imaging

(MRI) are among the additional procedures that must be performed in addition to the ones mentioned above. The best tools for determining the precise type of disease are the enormous magnets, radio waves, and computers used in MRI scans to display the most precise crisp images of the body. This examination can visualize the spine in greater detail and can accurately diagnose spinal stenosis, which is a narrowing of the spinal canal, if it is present. This test vividly shows the bone spurs on vertebral bodies in the spine, thickening of facet joints (the joints that connect the vertebrae to each other), and narrowing of the intervertebral disc spaces. Reducing the neck's range of motion is the primary goal of physical examinations(42,43).

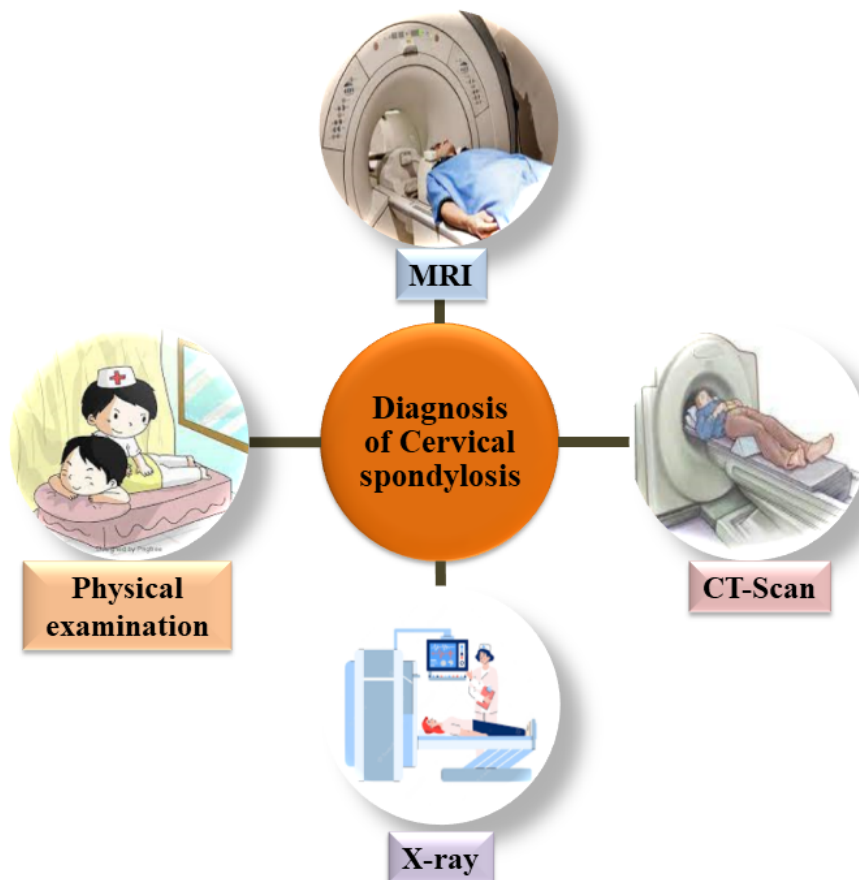


Fig.5:A few techniques for cervical spondylosis diagnosis.

❖ **Magnetic Resonance Imaging (MRI)**

MRI is the preferred imaging technique for assessing soft tissues and neurological systems. Without exposing the patient to radiation, it enables accurate vision of the entire cervical spine. Sagittal and axial cuts can reveal pathological alterations (such as herniated discs, bony spurs, ligamenta flava hypertrophy, or facet joint arthropathy) and assist measure the degree of nerve and cord compression. T2-weighted pictures with a strong spinal cord signal may indicate edema, inflammation, ischemia, myelomalacia, or gliosis. Considering the great occurrence of degenerative abnormalities on MRI in asymptomatic persons, MRI investigations should not be a

typical part of the diagnostic workup until warranted, despite their excellent sensitivity for detecting spondylotic alterations(44,45).

❖ **X-ray**

In the absence of "red flag" symptoms, plain radiographs are an adequate initial imaging investigation for neck and upper extremity pain. However, the presence of neck pain does not always correspond well with degenerative changes visible on imaging. Osteophyte formation, disc space narrowing, endplate sclerosis, degenerative alterations of the facet and uncovertebral joints, and calcified/ossified soft tissues are common radiographic findings. AP, lateral, and oblique views of the spine are suitable evaluate for foraminal stenosis, sagittal alignment, and the size of spinal canal. By comparing the sagittal diameter of the spinal canal to the sagittal diameter of the vertebral body, the Torg-Pavlov ratio can be calculated. When the ratio is less than 0.8, cervical stenosis is present. The normal value is 1.0. If there is a worry about ligamentous instability, flexion and extension views should also be taken into account(46).

❖ **Electromyogram (EMG)**

When diagnosing cervical radiculopathy, EMG can be a useful adjunct to neuroimaging results. It helps distinguish nerve root compression from other probable concurrent neurologic illnesses, such as peripheral neuropathies, entrapment neuropathies, brachial plexopathies, myopathies, and motor neuron diseases(47).

❖ **Discogram**

Rarely is provocative discography required for cervical spondylosis. It is helpful for the assessment of individuals with numerous herniations or cervical discogenic discomfort for whom surgery is quite likely. The diagnostic approach is still debatable, though, because it might quicken the deterioration of healthy discs(48).

❖ **Computed Tomography (CT)**

In the presence of uncovertebral or facet hypertrophy, CT offers a better delineation of bony structures and is more sensitive than plain radiography in diagnosing intervertebral foraminal stenosis. For the assessment of soft tissues and nerve root compression, it is fewer sensitive than MRI(47).

❖ **CT Myelogram**

The best use of CT is in conjunction with intrathecal contrast injection (myelography) to more accurately assess the site and degree of neural compression. Although it is more intrusive than an MRI, it may be an option for patients who cannot undergo an MRI due to a pacemaker or who have hardware artifacts(47).

CURRENT OPTIONS FOR CERVICAL SPONDYLOSIS TREATMENTS

There are numerous ways to treat cervical spondylosis and the radiculopathy and myelopathy it causes. They can be separated into suggestions and nonsurgical procedures. Treating each patient as an individual is the most crucial thing to keep in mind. adjusting the course of treatment in accordance with the patient's physical state, symptoms, and pathology. If the patient exhibits myelopathy symptoms and imaging tests reveal significant stenosis, surgery is required. Although the time period can be relatively extensive and there may be lengthy periods without worsening, the natural course of myelopathy is one of steady deterioration over time. Surgery is the only option for potential symptom relief while the patient is in good health; at the very least, if successful, surgery will typically stop the deterioration. Both nonsurgical and surgical procedures are reasonable, excluding severe myelopathy. The use of analgesics for pain, anticonvulsants or antidepressants for radicular pain, steroids to reduce inflammation surrounding neural structures, and muscle relaxants are some of the medical therapeutic possibilities(49). Strengthening the neck's muscles and supporting ligaments with physical therapy is helpful, and traction can assist relieve the nerve compression that results from foraminal stenosis. For patients with radiculopathy, epidural steroid injections are another alternative. There are several additional therapeutic alternatives, including massage, acupuncture, and chiropractic adjustments. With varying degrees of efficacy and value, local applications of heat, ice, and electrical stimulation have been employed. Axial neck pain, which can result from degenerating disks, hypertrophic facet joints, developing osteophytes, or bony end plates, is the main symptom of cervical spondylosis. The first line of treatment in this case is nonsteroidal anti-inflammatory medicines. If nonsteroidal anti-inflammatory medicines do not offer sufficient relief or are not well tolerated due to adverse effects, therapy may be advanced to oral opioids. Surgery is an option for patients with radicular discomfort whose investigations showed root compression, particularly if the pain and/or neurological deficiency are impairing quality of life. The location of the pathology determines the surgical strategy. If the pathology lies lateral to the spinal cord, a posterior approach may be an option in some situations rather than an anterior one. The surgical alternatives include anterior discectomy and interbody fusion, posterior foraminal decompression, either through a less invasive surgery or a more traditional laminectomy(50,51). The study front cervical discectomy accompanied by the implantation of an artificial disk is a more recent approach. When radiculopathy or myelopathy call for an anterior decompression, this is helpful. The spinal alignment must be generally normal, and the facet joints must be comparatively well preserved. In patients with advanced spondylosis, the artificial disk is therefore of limited use. Surgery can sometimes help patients with axial discomfort. However, these patients should use all nonsurgical options, and ideally, their imaging tests should show only one or two stages of illness. To ensure that the anomalies on the imaging scans are the cause of the pain, they should have a confirmatory test, which is typically a favorable response to facet injections. A modest number of wellchosen patients can be expected to have effective pain alleviation. The preferred surgical procedure, whether performed from an anterior or posterior approach, is often fusion. There are three options: posterior lateral mass screw fusion, anterior cervical discectomy with fusion, and anterior and posterior fusion combined. In addition to the health of the bone, spinal alignment, the condition of segments that will be adjacent to the fusion, and various other considerations, patients frequently have a mix of pain and myelopathy/radiculopathy. The surgical strategy must take these issues into

account(5,52).The main goals of treatment are to lessen discomfort and restore normal function. Anti-inflammatory medications (non-steroidal anti-inflammatory drugs) are provided for brief periods of time to lessen the pain associated with inflammation, but they should never be taken without consulting a doctor first. The nature of treatment is often conservative. In addition to alternative therapies including massage, chiropractic, and trigger-point therapy, patient education on lifestyle changes, (NSAIDs), and physical therapy is promoted to manage spondylosis symptoms. You might consider acupuncture and yoga(53–56).

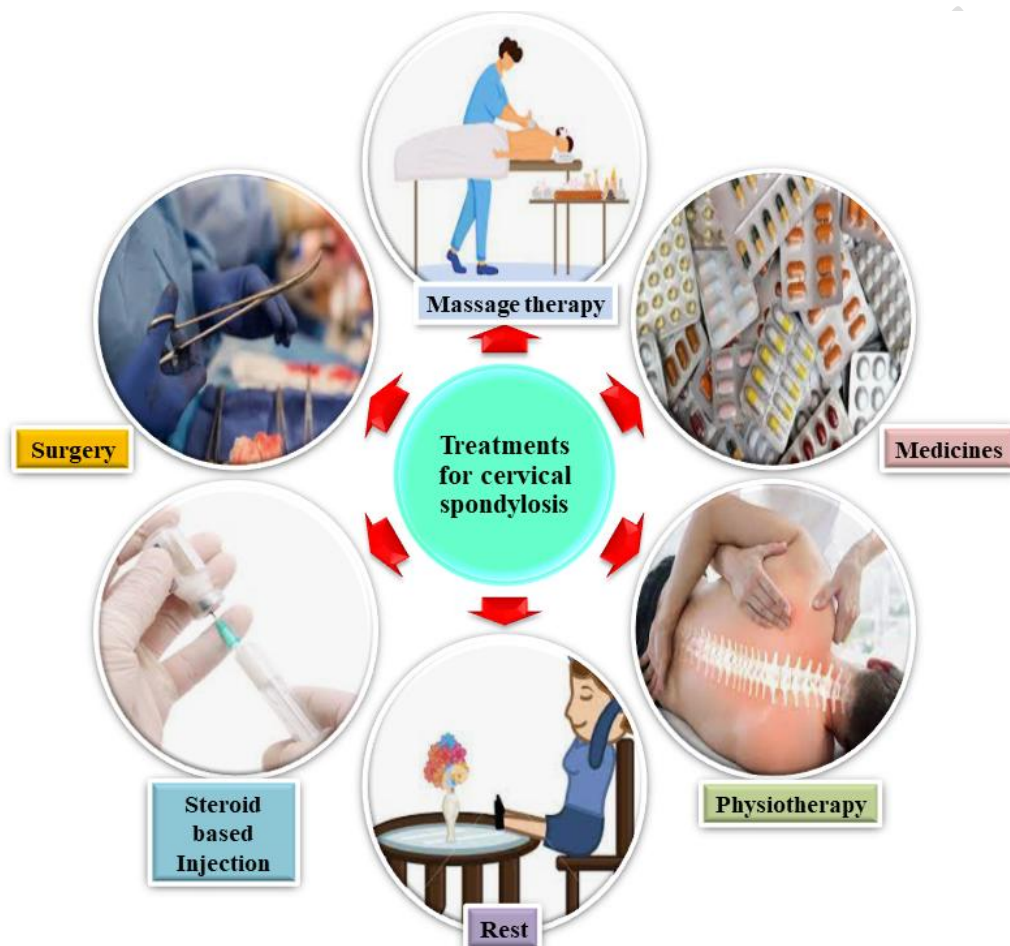

Fig.6:Some significant cervical spondylosis treatment options.

❖ Non-surgical Treatments

A four to six-week course of physical therapy, which includes isometric and resistance exercises to strengthen the neck and upper back muscles, serves as the cornerstone of non-surgical treatment. For pain management, physicians may prescribe pharmacologic substances such as nonsteroidal anti-inflammatory medications (NSAIDs), oral steroids, muscle relaxants, anticonvulsants, and antidepressants. Due to their potential side effects, opioid analgesics are not advised as first-line treatment or for long-term usage in the treatment of refractory axial neck pain. Consideration can be given to durable medical equipment for symptomatic alleviation. Acute neck pain and spasms might occasionally be relieved temporarily by wearing a gentle

cervical collar. The usage of a cervical pillow at night could reduce neck pain by assisting in the preservation of the healthy cervical lordosis, which would enhance the distribution of biomechanical loads between discs and increase the quality of sleep. Physical modalities include cervical traction, heat, cold, therapeutic ultrasound, massage, and transcutaneous electrical nerve stimulator (TENS) were found to have insufficient evidence in a 2001 meta-analysis by the Philadelphia Panel for the treatment of acute or chronic neck pain(57).To relieve the nerve root compression that results from foraminal stenosis, cervical traction may be used on patients who have radicular pain.Myofascial trigger points can cause pain in the neck, shoulder, and upper arm, which can be treated with trigger point injections. Epidural steroid injections (ESIs), injections into the zygapophysial (facet) joint, medial branch blocks, and radiofrequency lesioning (RFL) are some of the most invasive interventional therapeutic options. According to Conger et al.'s comprehensive review and meta-analysis published in 2019, at the one- and three-month follow-ups following cervical transforaminal ESIs, at least 50% of the patients with cervical radicular pain reported at least a 50% pain reduction.40% to 70% of individuals who had interlaminar or transforaminal ESIs for the treatment of cervical radiculopathy have reported long-term success. Long-term pain reduction was noted with cervical RFLs, MBBs, and facet joint injections in a 2015(58,59).

❖ Surgical Treatments

Patients with severe or worsening cervical myelopathy, as well as those who experience chronic axial neck discomfort or cervical radiculopathy after non-operative treatments have failed, should think about having surgery. Additionally, these afflicted people must have a pathological disease that matches their clinical characteristics and has been seen in neuroimaging investigations. The surgical strategy is determined by the clinical syndrome and the pathological site.An intervertebral disc replacement using an autograft, allograft, or artificial intervertebral disc is performed after a cervical discectomy or corpectomy in the anterior approach. Although the use of anterior plates, metallic cages, and artificial spacers in combination with bone transplants has led to comparable fusion rates, the long-term effects are still unknown. An anterior technique is recommended for individuals with central or bilateral disc herniations that cause radicular discomfort, but a lateral disc lesion can be treated with either an anterior or posterior approach. Treatment for patients with myelopathy, pathological compression up to three levels, or when cervical lordosis is lost involves anterior cervical discectomy and fusion (ACDF).Laminotomy-foraminotomy, laminoplasty, and laminectomy are all parts of the posterior approach. Patients with foraminal stenosis brought on by the growth of bone spurs or the herniation of a lateral disc can benefit from foraminotomy alone. In patients who need decompression at four or more levels or whose anterior column is already fused, laminectomy or laminoplasty is a clinical alternative. In order for the spinal cord to shift dorsally after decompression, a preserved cervical lordosis is essential for a posterior approach. In order to maximize the posterior shift of the spinal cord and enable patients with flexible cervical kyphosis return to normal lordosis, further cervical posterior instrumentation will be needed(47,60).

❖ Alternative treatments

Acupuncture: This treatment relieves symptoms by reducing stress and promoting the body's natural healing process by inserting extremely tiny needles into a number of critical places on the body. A mild, restorative form of yoga: A patient can get relaxation and symptom alleviation by doing a sequence of easy prescribed yoga poses, which are specifically designed to relieve stress and heal injuries. Chiropractic manipulation: Misaligned spinal vertebrae that put strain on delicate neural structures can be treated, which helps to lessen inflammation and enhance joint performance. Mechanical traction is an approach that is frequently utilized. Because it encourages immobility of the cervical region and enlarges the foraminal apertures, this type of treatment might be beneficial. In order to preserve the strength of the neck muscles, cervical exercises have been recommended for individuals with cervical spondylosis. Exercises that stretch the neck and upper back, along with some modest aerobic activity, are also beneficial. Exercise for cervical retraction: The patient is told to carefully move the head back across the spine as far as they can while keeping the head and eyes level. Exercise for cervical extension: the patient is taught to lift their chin up, retract their cervical spine, and extend their cervical spine all the way. The patient is then told to make two or three tiny head oscillations from right to left. Patient will take back to the retracted position, tuck chin, and then return head to midline position. Deep neck flexor exercise: To minimize activation of the sternocleidomastoid muscle during the deep neck flexor contraction, the patient is encouraged to slowly nod the head and flatten the curvature of the neck without pulling the head back. Scapular Strengthening Exercises: These are effective treatments for spondylosis-related neck, back, and inflammatory discomfort. Only symptomatic alleviation is shown with thermal therapy, and ultrasonography suggests that in some patients, more intrusive procedures like epidurals may be beneficial. Effects unfavorable to uncommon work: People who lift heavy objects with their heads or shoulders frequently develop cervical spondylosis. Another significant cause of neck pain is heavy activities, such as lifting awkwardly sized objects or engaging in particular yoga poses that severely impact the neck's structural elements. Executing tasks that require prolonged bending to one side without switching to the other side is another crucial component. Additionally, all such activities as incorrect sleeping positions, using pillows and mattresses that are too soft, watching TV while seated in an awkward position that strains the neck, sleeping while driving long distances and using a phone for extended periods of time, forward bending and rotating the neck, prolonged sitting or standing, and choosing the wrong chair to sit in that forces the neck into an extended position are all known to cause neck pain(61).

❖ Few therapies

▪ Physical therapy

Physical therapy for spondylosis primarily aims to improve the strength and flexibility of the core muscles that support the spine, especially those close to the site of degeneration. Molded cervical pillows can help some people with their symptoms by better aligning their spine while they sleep. The restriction of neck motion caused by immobilization lessens nerve irritability. It is advised to use soft cervical collars, especially during the day(61).

▪ Cold therapy

This method of treatment involves applying a variety of tools to the painful areas several times a day for up to 20 minutes at a time, such as reusable cold packs, instant disposable ice packs, plastic baggies filled with ice and wrapped in towels, frozen towels, or sponges(61).

- **Heat therapy**

In addition to offering comfort and promoting relaxation, this easily accessible free treatment that can be administered at home also helps to reduce back pain by widening the blood vessels in the muscles that surround the spine, increasing the flow of oxygen and nutrients that promotes the healing of damaged tissue(61).

- **Manual therapy**

For individuals with cervical spondylosis, this method of massage, mobilization, and manipulation may offer additional alleviation. In some patients, manual traction may be superior to mechanical traction(14,61).

- ❖ **Self-care for cervical spondylosis at home**

Due to the fact that spondylosis-related pain frequently gets better or goes away after several days, home treatment is crucial. Experts have discovered that bed rest extends the healing process. Therefore, it is advised to carry on with regular or almost regular activities. However, avoid doing anything that can make the issue worse, such hard lifting. For back and neck pain brought on by spondylosis, some patients find that applying heat or ice is beneficial. For some with low back pain, sleeping with a pillow between their legs may be beneficial. Neck pain sufferers can utilize specialized pillows designed to provide more cervical spine support and observe the relief. Regaining flexibility, core strength, and versatility in motion may be accomplished with the help of physical therapy. Pain relief may also come from decompressive treatments like mechanical traction and manual mobilization. According to some, a strong commitment to postural alteration is required if you want to get the most out of decompression of data adjustments, and flexibility therapy(62).

CONCLUSION AND FUTURE DIRECTION

A thorough introduction to cervical spondylosis is provided in the opening portion of our review articles, which also covers its aetiology, pathophysiology, histology, risk factors, therapy options, including non-surgical and surgery, and symptoms. Exercise and natural supplements take time but produce good results, even though pharmaceutical treatments don't have any negative side effects. To learn more about the best way to treat cervical spondylosis, additional randomised controlled studies must be conducted. We intend to continue our work on cervical spondylosis research. In our country or state, a second study incorporating counseling will be carried out with the assistance of our colleagues in order to assess patients' physical and mental health and to provide a more comprehensive understanding of cervical spondylosis and its improved treatment.

Table.1: Current status of clinical trials on Cervical spondylosis.

Drug	Mode of administration	Disease	Enrollment	Allocation/Intervention model/Masking	Official Title of the study	Status	Clinical trial	Year
conventional physical therapy	Interventional	Cervical spondylosis	69	Randomized/ Parallel Assignment/Double (Participant Outcomes Assessor)	The Effect of Kinesio Taping on Cervical Proprioception Sense, Pain, Disability and Quality of Life in Patients With Cervical Spondylosis	NA	NCT05313763	2022
Diaphragmatic and pursed lip breathing	Interventional	Cervical spondylosis	72	Randomized/ Parallel Assignment/ Single	Effects of Breathing Exercises on Pain, Range of Motion and Neck Disability in Patients With Cervical Spondylosis	NA	NCT05086367	2021
Yoga Chikitsa	Interventional	Cervical spondylosis	117	Randomized/ Parallel Assignment/ None (Open Label)	Yoga Chikitsa for Neck Pain Caused by Cervical Spondylosis: a Randomized Controlled Pilot Trial	NA	NCT03526965	2018
Segmental Mobilization/ Entire Spine Mobilization	Interventional	Cervical spondylosis	30	Randomized/ Parallel Assignment/ None (Open Label)	Comparison Between the Segmental Mobilization and Entire Segmental Spine Mobilization in Cervical Spondylosis	NA	NCT04287634	2020
DTI - Diffusor Tensor Imaging	Interventional	Cervical spondylosis	40	Non-Randomized/ Parallel Assignment/ None (Open Label)	Structural Spinal Cord Integrity in Patients With Cervical Spondylosis in Relation to Clinical Status	NA	NCT01243684	2015
Enhanced recovery after surgery	Observational	Cervical spondylosis	2000	Cohort	Evaluation of the Effect of Enhanced Recovery After Surgery for Cervical Surgery	NA	NCT04955496	2021
Yoga Therapy	Interventional	Cervical spondylosis	62	Randomized/ Parallel Assignment/Single (Outcomes Assessor)	Effectiveness of Yoga Therapy for Neck Pain Relief in Patients With Cervical Spondylosis	NA	NCT04113473	2019
ACDF	Observational	Cervical spondylosis	269	Cohort	Cervical Spondylotic Myelopathy - Cost Observational Surgical Trial	NA	NCT05994404	2023
gaze stabilization	Interventional	Cervical spondylo	32	Randomized/ Parallel	Effects of Gaze Stabilization Exercises on Dizziness,	NA	NCT05707130	2023

exercises		sis		Assignment/ None (Open Label)	Balance and Quality of Life in Patients With Cervical Spondylosis.			
NA	Observational	Cervical spondylosis	26	Case-Control	Diffusion Tensor Imaging of the Brain and Cervical Spine: Evaluation of Reproducibility in Normal Subjects and Diagnostic Utility in Patients With Cervical Spondylotic Myelopathy	NA	NCT01868958	2015
Pregabalin	Interventional	Cervical spondylosis	50	N/A/ Single Group Assignment/ None (Open Label)	Open Labelled Study of Pregabalin in the Treatment of Neuropathic Pain in Cervical Myeloradiculopathy (Pregabalin and Radicular Pain Study (PARPS))	Phase-4	NCT01061697	2011
Dry needling/ Physical therapy and rehabilitation	Interventional	Cervical spondylosis	70	Randomized/ Parallel Assignment/Single (Outcomes Assessor)	The Effect of Dry Needling Treatment Combined With Physical Therapy in Patients With Cervical Spondylosis: A Randomized Controlled Study	NA	NCT05744778	2023
inhalation anesthesia with isoflurane vs. TIVA with propofol	Interventional	Cervical spondylosis	200	Randomized/ Parallel Assignment/ None (Open Label)	Does Inhalational Anesthesia Accelerate Postoperative Cognitive Decline?	NA	NCT00788008	2015
ViBone	Observational	Cervical spondylosis	95	Case-Only	A Prospective, Post-Market, Multi-Center Study Evaluating ViBone® in Cervical and Lumbar Spine Fusion	NA	NCT03425682	2021
Transcutaneous Electrical Nerve Stimulation (TENS)	Interventional	Cervical spondylosis	90	Randomized/ Parallel Assignment/ None (Open Label)	Short-Term Effects of Kinesio Taping on Pain and Functionality in Patients With Cervical Spine Surgery	NA	NCT04039581	2021
Cervical Orthosis (CO)/ No Orthosis	Interventional	Cervical spondylosis	64	Randomized/ Parallel Assignment/ None (Open Label)	A Randomized Trial of Cervical Orthosis Versus no Orthosis Following Multi-level Posterior Cervical Fusion	NA	NCT04308122	2022
Cervical spinal surgery	Observational	Cervical spondylosis	100	Cohort	Change of Lumbar Symptom After Surgical Treatment for Patients With Cervical Stenosis	NA	NCT03089931	2020
ActiPatch/ Etoricoxib 60 mg	Interventional	Cervical spondylosis	180	Randomized/ Parallel Assignment/None (Open Label)	The Efficacy/Safety Profile Of Pulsed Shortwave Therapy in Cervical Osteoarthritis: A Comparison Study Against Etoricoxib	NA	NCT03542955	2019
ViviGen	Observational	Cervical spondylo	100	Cohort	A Multi-Center, Prospective, Single-Arm Study of Patients	NA	NCT02814825	2021

		sis			Undergoing a Two or Three Level ACDF Using ViviGen Cellular Bone Matrix in Conjunction With Cervical Allograft Spacers and DePuy Synthes Spine Anterior Cervical Plate Systems			
decompressive cervical surgery	Observational	Cervical spondylosis	50	Cohort	Decompressive Cervical Surgery for Antihypertensive Effect in Patients With Cervical Spondylosis and Hypertension-A Cohort Study	NA	NCT02016768	2020
10-second hand grip and release test	Observational	Cervical spondylosis	1380	Cohort	Evaluation of the Screening Effect of Artificial Intelligence Hand Activity Evaluation System for Cervical Spondylosis	NA	NCT06041542	2023
NA	Observational	Cervical spondylosis	31	Case-Control	High-Resolution Diffusion Tensor Imaging (DTI) of the Cervical Spinal Cord in the Setting of Spinal Cord Injury (SCI)	NA	NCT01407705	2014
Ventral Surgical Decompression with Instrumented Fusion	Interventional	Cervical spondylosis	103	Non-Randomized/ Parallel Assignment/ None (Open Label)	The CSM Trial: A Multicenter Study Comparing Ventral to Dorsal Surgery for Cervical Spondylotic Myelopathy	Phase-3	NCT00506558	2012
Laminectomy and Laminoplasty	Observational	Cervical spondylosis	321	Other	An Assessment of Surgical Techniques for Treating Cervical Spondylotic Myelopathy	NA	NCT00285337	2017
Anterior cervical discectomy and fusion (ACDF)	Interventional	Cervical spondylosis	136	Randomized/ Parallel Assignment/Single (Participant)	Treatment of Cervical Radiculopathy With Arthroplasty Compared With Discectomy With Fusion and Cage (ACDF). Clinical, Radiological and Biomechanical Aspects. A Randomized Multicenter Study.	NA	NCT00735176	2019
Soft or stiff cervical collar(device), neck school(behavior)	Interventional	Cervical spondylosis	120	Randomized/ Parallel Assignment/ None (Open Label)	Effect of Conservative Treatment With Cervical Collar in Patients With Cervical Radiculopathy and Radicular Pain. A Randomized Controlled Study	Phase-2	NCT00395798	2011
1 or 2-Level ACDF utilizing BIO4 with	Interventional	Cervical spondylosis	20	N/A/ Single Group Assignment/ None (Open Label)	Clinical and Radiographic Outcomes of BIO4 Bone Matrix in Patients Undergoing 1 or 2-Level	Phase-4	NCT03077204	2022

Bio AVS Cervical Allograft (with graft window).					Anterior Cervical Discectomy and Fusion Surgery			
NeoFuse / Allograft	Interventional	Cervical spondylosis	24	Randomized/ Parallel Assignment/ Single (Outcomes Assessor)	Phase 2 Study Evaluating Safety and Preliminary Efficacy of NeoFuse When Combined With MasterGraft Matrix in Subjects Undergoing Multi-Level Anterior Cervical Discectomy and Fusion With Anterior Cervical Plate Fixation	Phase-2	NCT01097486	2019
NeoFuse / MasterGraft Granules	Interventional	Cervical spondylosis	12	Randomized/ Parallel Assignment/ Single (Participant)	Phase 2 Study Evaluating Safety and Preliminary Efficacy of NeoFuse When Combined With MasterGraft Matrix in Subjects Undergoing Multi-Level Anterior Cervical Discectomy and Fusion With Anterior Cervical Plate Fixation	Phase-1 & 2	NCT01106417	2020
NA	Observational	Cervical spondylosis	69	Case-Only	VariLift Lumbar and Cervical Patient Registry	NA	NCT01944345	2016
NA	Observational	Cervical spondylosis	60	Cohort	Prospective Follow-up Study of the Aesculap Quintex® Anterior Cervical Plating System After a Minimum of One Year	NA	NCT04489394	2020
NA	Observational	Cervical spondylosis	100	Cohort	Multicenter PMCF Study on the Safety and Performance of CESPAC 3D - A Prospective Study on Total Indications	NA	NCT04477447	2023
C3 laminectomy/ C3 laminoplasty	Interventional	Cervical spondylosis	126	Randomized/ Parallel Assignment/ Single (Participant)	Randomized Controlled Trial: Comparison of Radiological and Axial Pain Outcome Between C3-6 Open Door Laminoplasty and C3 Laminectomy With Cervical Laminoplasty	NA	NCT05006495	2021
MRI with DBSI technology	Observational	Cervical spondylosis	71	Cohort	Predictive Value of Diffusion MRI in Cervical Spondylotic Myelopathy	NA	NCT03296592	2023
ACDF/ ACD A	Interventional	Cervical spondylosis	198	Randomized/ Parallel Assignment/ Single (Participant)	Economic Evaluation of Anterior Cervical Discectomy With Arthroplasty Versus Anterior Cervical Discectomy With Fusion in the Surgical Treatment of Cervical Degenerative	NA	NCT04623593	2022

					Disc Disease, a Randomized Controlled Trial			
ACAF/ Laminoplasty	Interventional	Cervical spondylosis	164	Randomized/ Parallel Assignment / None (Open Label)	An Open-label Randomized Multi-centre Study to Evaluate Anterior Controllable Antedisplacement and Fusion Versus Posterior Laminoplasty in Patients With Cervical Ossification of the Posterior Longitudinal Ligament	NA	NCT04968028	2023
AlloWrap Amniotic Membrane	Interventional	Cervical spondylosis	50	Randomized/ Parallel Assignment/ None (Open Label)	A Randomized, Controlled Study to Evaluate Effectiveness of AlloWrap® Amniotic Membrane for the Reduction of Post-Operative Soft Tissue Inflammation in Two-Level Anterior Cervical Discectomy and Fusion Procedures	NA	NCT04684901	2023
epidural electrical stimulation	Interventional	Cervical spondylosis	150	N/A/ Single Group Assignment/ None (Open Label)	Recording of Intraoperative Spinal Cord Stimulation and Monitoring	NA	NCT05356286	2022
3T MR Imaging of the cervical spinal cord	Interventional	Cervical spondylosis	100	Non-Randomized/ Parallel Assignment/None(Open Label)	Evaluating Advanced Imaging Techniques for Use in the Assessment of Degenerative Cervical Myelopathy	NA	NCT05242666	2022
Modified Cervical Retraction Exercises (MCRE)	Interventional	Cervical spondylosis	36	Randomized/ Parallel Assignment/Single (Participant)	Comparative Effects of Modified Cervical Retraction and Motor Control Therapeutics Exercises on Pain, Range of Motion and Functional Disability in Patients With Cervical Spondylosis	NA	NCT05916794	2023
Conventional physiotherapy	Interventional	Cervical spondylosis	76	Randomized/ Parallel Assignment/ None (Open Label)	Comparison of the Effects of Muscle Energy Technique and Mobilization Techniques on Cervical Proprioception and Motor Control in Patients With Cervical Spondylosis: A Randomized Controlled Study	NA	NCT04777318	2023
Upper fibers of trapezius stretching/ Standard care	Interventional	Cervical spondylosis	64		Efficacy of Upper Trapezius Stretching on Neck Pain, Range of Motion and Disability in Patients With Cervical Spondylosis: A Randomised Controlled Trial	NA	NCT05920564	2023

References

1. Wu JC, Ko CC, Yen YS, Huang WC, Chen WC, Lu L, Tu TH, Lo SS CH. Neurosurgical Focus. 2013;35(1):3171- 3182. 2013;35(1):1-4.
2. Ross J, Brant-Sawadzki M, Moore K et al. Diagnostic Imaging.
3. Richard C, Benzel EC, Williams L. Clark, Charles Richard, and Edward C. Benzel, eds. The cervical spine . Lippincott Williams & Wilkins, 2005. 2005;2005.
4. Lv Y, Tian W, Chen D, Liu Y, Wang L, Duan F. The prevalence and associated factors of symptomatic cervical Spondylosis in Chinese adults: A community-based cross-sectional study. BMC Musculoskelet Disord. 2018;19(1):1-12.
5. Takagi I, Eliyas JK, Stadlan N. Cervical Spondylosis: An Update on Pathophysiology, Clinical Manifestation, and Management Strategies. Disease-a-Month. 2011;57(10):583-91.
6. H.Bland J. Disorders of the Cervical Spine.
7. Mullin J, Shedid D, Benzel E. Overview of Cervical Spondylosis Pathophysiology and Biomechanics. World Spinal Column J WScJ. 2011;2(2):89-97.
8. Benzel EC. Benzel, Edward C. "Biomechanics of spine stabilization." Rolling Meadows (2001): 437-440.
9. Garfin SR. Cervical degenerative disorders: etiology, presentation, and imaging studies. Instr Course Lect. 2000;49:335-8.
10. Profile SEE. Cervical Spondylosis-A Review I nternational J ournal of A llied M edical S ciences and C linical R esearch (IJAMSCR) Cervical Spondylosis-A Review. 2016;(January):1-4.
11. Igwe A, Okoye G, Eyichukwu G, Ezema C, Egwuonwu A, Onwujekwe O. Treatment of Cervical Spondylosis in Southeast Nigeria: Benefits of Intermittent Alternating Upright Distraction and Flexion High Weight Cervical Traction. Br J Med Med Res. 2016;16(7):1-7.
12. Akimbo, S. R. A. et al. "Comparative efficacy study of Morind citrifolia (NONI) with selected physiotherapy modalities in the management of patients with cervical spondylosis." Nig J Med Rehab 1018 35- 41. 2005;18:17-9.
13. Binti Karim N, Chowdhury Asha A, Aminul Islam M, Mandal A, Islam T, Rahaman KS. Features of Neck Pain and its Related Factors Among Patients With Cervical Spondylosis. Int J Epidemiol Res. 2018;5(3):92-7.
14. Sankar R. Cervical spondylosis -causes and remedial measures. 2020;(January 2015).
15. Kokubo Y, Uchida K, Kobayashi S, Yayama T, Sato R, Nakajima H, et al. Herniated and spondylotic intervertebral discs of the human cervical spine: Histological and immunohistological findings in 500 en bloc surgical samples - Laboratory investigation. J Neurosurg Spine. 2008;9(3):285-95.
16. Ferrara LA. The Biomechanics of Cervical Spondylosis. Adv Orthop. 2012;2012:1-5.
17. Kelly JC, Groarke PJ, Butler JS, Poynton AR, O'Byrne JM. The Natural History and Clinical Syndromes of Degenerative Cervical Spondylosis. Adv Orthop. 2012;2012:1-5.
18. Hoy DG, Protani M, De R, Buchbinder R. The epidemiology of neck pain. Best Pract Res Clin Rheumatol. 2010;24(6):783-92.
19. Hurwitz EL, Randhawa K, Yu H, Côté P, Haldeman S. The Global Spine Care Initiative: a summary of the global burden of low back and neck pain studies. Eur Spine J [Internet]. 2018;27(0123456789):796-801. Available from: <https://doi.org/10.1007/s00586-017-5432-9>
20. Lu X, Tian Y, Wang SJ, Zhai JL, Zhuang QY, Cai SY, et al. Relationship between the small cervical vertebral body and the morbidity of cervical spondylosis. Med (United States). 2017;96(31).

21. Singh S, Kumar D KS. Risk factors in cervical spondylosis. *Journal of clinical orthopaedics and trauma*. 2014 Dec 31;5(4):221-6 [Internet]. 2014;39(1):1-15. Available from: <http://dx.doi.org/10.1016/j.biochi.2015.03.025><http://dx.doi.org/10.1038/nature10402><http://dx.doi.org/10.1038/nature21059><http://journal.stainkudus.ac.id/index.php/equilibrium/article/view/1268/1127><http://dx.doi.org/10.1038/nrmicro2577>
22. Binder AI. Cervical spondylosis and neck pain. *Br Med J*. 2007;334(7592):527-31.
23. Sharma S, Bhusal N. CERVICAL SPONDYLOSIS AND ITS PANCHKARMA MANAGEMENT A CERVICAL SPONDYLOSIS AND ITS PANCHKARMA MANAGEMENT- MANAGEMENT. 2019;(February).
24. Sun Y, Jin M, Yu T, Zhang J. Cardiovascular risk factors mediating the protective effect of education on cervical spondylosis risk. *Sci Rep* [Internet]. 2023;13(1):1-7. Available from: <https://doi.org/10.1038/s41598-023-28153-7>
25. On D, Of R, Intervertebral THE, In D, Region C. Discussion on Rupture of the Intervertebral Disc in the Cervical Region. *J R Soc Med*. 1948;41(8):509-16.
26. Bailey, Pearce M.D.1; Casamajor LMD 2. OSTEO-ARTHRITIS OF THE SPINE AS A CAUSE OF COMPRESSION OF THE SPINAL CORD AND ITS ROOTS: With Reports of Five Cases. *J Nerv Ment Dis* 38(10)p 588-609, Oct 191 [Internet]. 1911;21(2):11-2. Available from: <http://www.ncbi.nlm.nih.gov/pubmed/810049><http://doi.wiley.com/10.1002/anie.197505391><http://www.sciencedirect.com/science/article/pii/B9780857090409500205><http://www.ncbi.nlm.nih.gov/pubmed/21918515><http://www.cabi.org/cabebooks/ebook/20083217094>
27. Brain WR, Northfield D, Wilkinson M. The neurological manifestations of cervical spondylosis. *Brain*. 1952;75(2):187-225.
28. WA L. Guy's Hosp Rep.
29. Clarke E, Robinson PK. Cervical myelopathy: A complication of cervical spondylosis. *Brain*. 1956;79(3):483-510.
30. Wenzel, Carl and KW. Über die Krankheiten am Rückgrathe.
31. Scott E, Kerr D. Cervical Spondylosis. *Curr Ther Neurol Dis Text with CD-ROM*. 2005;(February):61-4.
32. ONO K, OTA H, TADA K, YAMAMOTO T. Cervical Myelopathy Secondary to Multiple Spondylotic Protrusions: A Clinicopathologic Study. *Spine (Phila Pa 1976)* [Internet]. 1977;2(2). Available from: https://journals.lww.com/spinejournal/fulltext/1977/06000/cervical_myelopathy_secondary_to_multiple.4.aspx
33. McCormack BM, Weinstein PR. Cervical spondylosis - An update. *West J Med*. 1996;165(1-2):43-51.
34. MR E. "Cervical radiculopathy.
35. DILLIN W, BOOTH R, CUCKLER J, BALDERSTON R, SIMEONE F, ROTHMAN R. Cervical Radiculopathy: A Review. *Spine (Phila Pa 1976)* [Internet]. 1986;11(10). Available from: https://journals.lww.com/spinejournal/fulltext/1986/12000/cervical_radiculopathy__a_review.3.aspx
36. Manning G, Carpenter J. Stress prevention: The 1 x 3 x 7 = 21 plan. *Clin Lab Manag Rev*. 1993;7(4):304-8.
37. Rosomoff HL, Fishbain D, Rosomoff RS. Chronic cervical pain: radiculopathy or brachialgia. Noninterventional treatment. *Spine (Phila Pa 1976)* [Internet]. 1992 Oct;17(10 Suppl):S362-6. Available from: https://journals.lww.com/spinejournal/Abstract/1992/10001/Chronic_Cervical_Pain__Radiculopathy_or.4.aspx
38. DENNO JJ, MEADOWS GR. Early Diagnosis of Cervical Spondylotic Myelopathy: A Useful Clinical Sign. *Spine (Phila Pa 1976)* [Internet]. 1991;16(12). Available from:

- https://journals.lww.com/spinejournal/fulltext/1991/12000/early_diagnosis_of_cervical_spondylotic.1.aspx
39. McCormick WE, Steinmetz MP, Benzel EC. Cervical spondylotic myelopathy: make the difficult diagnosis, then refer for surgery. *Cleve Clin J Med* [Internet]. 2003 Oct;70(10):899–904. Available from: <https://doi.org/10.3949/ccjm.70.10.899>
 40. VIIKARI-JUNTURA E, PORRAS M, LAASONEN EM. Validity of Clinical Tests in the Diagnosis of Root Compression in Cervical Disc Disease. *Spine (Phila Pa 1976)* [Internet]. 1989;14(3). Available from: https://journals.lww.com/spinejournal/fulltext/1989/03000/validity_of_clinical_tests_in_the_diagnosis_of.3.aspx
 41. Garfin S.R., Cervical degenerative disorders: Etiology, presentation, and imaging studies, 2000; 49: 335–345. 2000;2000.
 42. Brown BM, Schwartz RH, Frank E, Blank NK. Preoperative evaluation of cervical radiculopathy and myelopathy by surface-coil MR imaging. *Am J Roentgenol*. 1988;151(6):1205–12.
 43. Yamazaki T, Suzuki K, Yanaka K, Matsumura A. Dynamic computed tomography myelography for the investigation of cervical degenerative disease. *Neurol Med Chir (Tokyo)*. 2006;46(4):210–5.
 44. McCormick WE, Steinmetz MP, Benzel EE. Cervical spondylotic myelopathy: Make the difficult diagnosis, then refer for surgery. *Cleve Clin J Med*. 2003;70(10):899–904.
 45. Brinjikji W, Luetmer PH, Comstock B, Bresnahan BW, Chen LE, Deyo RA, et al. Systematic literature review of imaging features of spinal degeneration in asymptomatic populations. *Am J Neuroradiol*. 2015;36(4):811–6.
 46. McDonald MA, Kirsch CFE, Amin BY, Aulino JM, Bell AM, Cassidy RC, et al. ACR Appropriateness Criteria ® Cervical Neck Pain or Cervical Radiculopathy. *J Am Coll Radiol* [Internet]. 2019;16(5):S57–76. Available from: <https://doi.org/10.1016/j.jacr.2019.02.023>
 47. Kuo DT, Tadi P. Cervical Spondylosis. [Updated 2023 May 1]. In: StatPearls [Internet]. Treasure Island (FL): StatPearls Publishing; 2023 Jan-. Available from: <https://www.ncbi.nlm.nih.gov/books/NBK551557/>. 2023;551557.
 48. Cuellar JM, Stauff MP, Herzog RJ, Carrino JA, Baker GA, Carragee EJ. Does provocative discography cause clinically important injury to the lumbar intervertebral disc? A 10-year matched cohort study. *Spine J* [Internet]. 2016;16(3):273–80. Available from: <http://dx.doi.org/10.1016/j.spinee.2015.06.051>
 49. Mazanec D RA. Medical management of cervical spondylosis.
 50. Matz PG, Pritchard PR, Hadley MN. Anterior cervical approach for the treatment of cervical myelopathy. *Neurosurgery*. 2007;60(1 SUPPL.):64–70.
 51. Riew KD, Cheng I, Pimenta L, et al. Posterior cervical spine surgery for radiculopathy. *Neurosurgery* 2007;60:S57-63. 2007;2007.
 52. Wieser ES WJ. Surgery for neck pain.
 53. Dillin W. UG. Analysis of medications used in the treatment of cervical disk degeneration,. 1992; 233 421-33. 1992;19:709–15.
 54. Huang RC, Girardi FP, Poynton AR, Cammisa Frank P. Jr. Treatment of Multilevel Cervical Spondylotic Myeloradiculopathy With Posterior Decompression and Fusion With Lateral Mass Plate Fixation and Local Bone Graft. *Clin Spine Surg* [Internet]. 2003;16(2). Available from: https://journals.lww.com/jspinaldisorders/fulltext/2003/04000/treatment_of_multilevel_cervical_spondylotic.2.aspx
 55. Papadopoulos SM, Hoff JT. Anatomical treatment of cervical spondylosis. *Clin Neurosurg*. 1994;41:270–85.

56. Emery SE. Cervical Spondylotic Myelopathy: Diagnosis and Treatment. JAAOS - J Am Acad Orthop Surg [Internet]. 2001;9(6). Available from: https://journals.lww.com/jaaos/fulltext/2001/11000/cervical_spondylotic_myelopathy__diagnosis_and.3.aspx
57. Philadelphia Panel evidence-based clinical practice guidelines on selected rehabilitation interventions for neck pain. Phys Ther. 2001 Oct;81(10):1701–17.
58. Conger A, Cushman DM, Speckman RA, Burnham T, Teramoto M, McCormick ZL. The effectiveness of fluoroscopically guided cervical transforaminal epidural steroid injection for the treatment of radicular pain; A systematic review and meta-analysis. Pain Med (United States). 2020;21(1):41–54.
59. Manchikanti L, Nampiaparampil DE, Candido KD, Bakshi S, Grider JS, Falco FJE, et al. Do Cervical epidural injections provide long-term relief in neck and upper extremity pain? A systematic review. Pain Physician. 2015;18(1):39–60.
60. Rao RD, Currier BL, Albert TJ, Bono CM, Marawar S V, Poelstra KA, et al. Degenerative Cervical Spondylosis: Clinical Syndromes, Pathogenesis, and Management. JBJS [Internet]. 2007;89(6). Available from: https://journals.lww.com/jbjsjournal/fulltext/2007/06000/degenerative_cervical_spondylosis__clinical.26.aspx
61. H. V. The management of cervical spondylosis.
62. Swezey RL, Swezey AM, Warner K. EFFICACY OF HOME CERVICAL TRACTION THERAPY1. Am J Phys Med Rehabil [Internet]. 1999;78(1). Available from: https://journals.lww.com/ajpmr/fulltext/1999/01000/efficacy_of_home_cervical_traction_therapy1.8.aspx