

Functional outcome in an acute acetabular fracture& Diagnosis, Management and prognosis following surgical treatment: Current concepts

ABSTRACT:

To evaluate the functional results of early surgical treatment for displaced acetabular fractures, as well as the complications involved.

Methods: A study involving 23 patients aged 18–55 with acetabular fractures from 2017–2019 followed their treatment using open reduction and internal fixation using, plate, and internal screw. Patients were excluded from the study due to factors like pregnancy, infection, poor physical conditions, and previous diseases. The study used Kocher, Langenbeck, and ilioinguinal approaches for postoperative treatment, but no condition was cured.

Result: - A total of 23 patients were operated. Union was achieved in anatomical position in 20 (86.95%) patients and in malposition in 3 (13.05%) patients. Excellent results were obtained in 12 (52.17%) patients, good results in 5 (21.73%), fair results in 3 (13.04%), and poor results in 3 (13.04%) patients. Postoperative complications included infection 0 (0%), heterotopic ossification 0, sciatic nerve injury (1) (4.34%), and avascular necrosis in 2 (8.60%) patients.

Conclusion: - Acetabular fractures are orthopedic injuries requiring careful attention and treatment. Earlier Acetabular Surgery were difficult due to poor anatomy and surgical procedures. Advances in CT scans and 3D reconstructions have made fracture patterns more common. Open reduction and internal fixation are the preferred treatments, aiming to reduce body size and achieve stabilization quickly. However, the study has limitations due to the small number of cases and its short duration.

Keywords: Acetabular fracture, Kocher Langenbeck, Ilioinguinal, heterotropic, ossification

Introduction: - Most acetabular fractures occur in young people who sustain serious injuries, most often from car accidents or trauma. The force coming from the femur is transmitted from the femoral head to the acetabulum. The direction and magnitude of the force and the position of the femoral head determine the shape of the acetabular fracture.^{1,2} Anatomical and radiological classification plays an important role and is the first step in determining treatment. Once the acetabular fracture pattern is obtained, appropriate treatment can be planned and applied. Associated injuries, often life-threatening, are also important, as 50% of patients often suffer from more than one injury and many do not. Multiple Bone fractures, head trauma, chest, abdominal, and pelvic ring injuries are the most common injuries.³ Acetabular fractures are diagnostic and therapeutic challenge for orthopedic surgeons. Acetabular fractures constitute 10% of all pelvic traumas and have a total incidence of approximately 3 patients/100,000/year, usually secondary to high energy, these injuries usually occur after multiple injury in accidents in young, active patients and are often associated with internal organ injuries.^{5,6} whereas in the elderly (> 60 years of age), most injuries are from falls from height. The incidence of acetabular fractures is quite high. Bleeding is the most urgent and dangerous problem. The onset of pelvic acetabular trauma is identified by due to chronic pain, postural and gait disorders, or permanent neurological deficits. Lower urinary tract, urogenital, or rectal dysfunction.⁹ **Hip osteoarthritis,**

often with avascular necrosis of head of femur and heterotrophic ossification of the femoral head,¹⁰ Acetabular fracture is a serious orthopedic problem that is not adequately treated and causes illness and deformity in many patients. There is a lot of concern about these bones because many patients are treated poorly. However, many people report good results with conservative treatment but worry about complication of heterotrophic ossification and inadequate reduction with surgical treatment. Until now, all acetabular fractures were treated mainly by the closed method. Acetabular fractures are bone fractures that require specialized knowledge to obtain a good result. Treatment of acetabular fractures is difficult due to the difficulty in understanding the fracture pattern, the difficulty of surgery, and the limited anatomy knowledge. Conservative treatment of the acetabular bone fracture has been criticized due to failing to anatomical Reduction of the joint and leading to the development of osteoarthritis.^{7,8} The purpose of the research was to assess the functional results of the acetabulum fracture surgery. The difficulties should be assessed in order to weigh the benefits and drawbacks.

Material and method: -This was an original research article prospective study conducted in Govt. Medical College Kota and Associated Hospital from June 2017 to December 2019. After ethical clearance obtain from ethical committee, in this Research 23 patients with acetabular fractures were followed, were treated with screw and plate The process includes: 1. male and female patients, ages 18 to 55, Patients presented within 3 weeks of injury. All patients had an acetabular fracture with > 2 mm of displacement.

Exclusion criteria: - The patient disagrees. Pregnancy, No displaced and minimally displaced (<2 mm) acetabular fractures Patient age: <18 or >55 years, Localized soft tissue infection, Patients with poor physical conditions, such as heart disease and respiratory failure, Patients with previous ankylosing spondylitis, rheumatoid arthritis, secondary arthritis, femoral head avascular necrosis, and other diseases, Femoral neck, femoral head, femoral shaft, distal femur, tibia, bones of other limbs, ankle circumference, and other pelvic bones

The data collection process is prospective. Obtain verbal and written consent. Clinical examination and radiological examination and postoperative complications are recorded in a special form prepared for this purpose. All patients undergoing acetabular surgery have pre- and post-operative x-rays taken. Patients were followed for 3 months after surgery. At each visit, patients will be examined and radiographs taken. The examination includes examination of the range of motion (ROM) of the hip joint, gait and adequate muscle strength, especially of the quadriceps, hamstrings and gluteal muscles. All patients were applied skeletal traction for 3 weeks after the surgery and were discharged after 8 (10-12) days with instructions for range of motion exercises. Walking without weight starts 6 weeks after surgery, and walking with full weight starts 3 months after surgery. The Kocher Langenback technique was used to treat fractures of the posterior lip, posterior column, transverse fractures, and T fractures. The ilioinguinal and Kocher Langenbeck approaches were used to treat fractures of the anterior column. No case was treated with extensile approach. Acetabular Recon Plates and cortical screws were the implants in use.

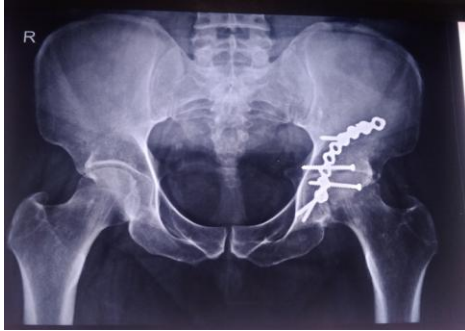


Figure: -1 This is an x-ray of the pelvis, AP view, showing the posterior system. The acetabular bone was fixed with an exploration plate using the Kocher Lagenbeck approach.

Results: - All patients with acetabular fractures were treated with **Acetabular reconstruction plates and screws**. A total of 25 patients were selected for this study, and two of them were lost to follow-up. Twenty-three patients were included in the study and followed regularly. Clinical evaluation was made using the Merle d'Aubigne-Postel score, and radiological evaluation was made using the Matta model. The following observations are noted: Among the 23 patients in this study, the proportion of men was higher; 86.95% were male and 13.05% were female. The youngest patient in our study was 21 years old, and the oldest patient was 54 years old. Most patients (14 out of 23) were between the ages of 20 and 40. 4 of 23 patients had diabetes (1 patient had hypertension and diabetes, 3 patients had hypertension only). For most patients, the mechanism of injury is a traffic accident (RTA), including 22 patients (95.66%); in our study, height loss occurred in 1 patient (4.34%). In this study, all bones were classified according to the Letournel and Judet classification, and in our study, the posterior bones were the most common with 56.52%. During our study, the time between injury and surgery was between 2 and 20 days, and most (74%) were operated on within 7 days. All cases are processed within 20 days. The reasons for postponing the choice of surgery are comorbidities and poor health status. The severity of the patient's injury. The average length of stay in this study was 11.5 days. At first admission, one patient had a major sciatic nerve, and this nerve was not observed to be displaced or seriously torn during the surgery. At the end of recovery, partial recovery was achieved in sciatic nerve patients. A preoperative CT scan shows a closed posterior wall margin in one patient. Only two of the 23 patients underwent autologous bone grafting to fill the gap. Preoperative CT scans revealed vascular lesions (loose bodies) in three cases. In this study, a retrograde osteotomy was performed in three patients to provide better access during surgery. In preliminary evaluation, CT showed changes of 2 cm in 15 patients and >2 cm in 8 patients. The mean displacement was 1.90 cm, SD 0.521. Radiological results were evaluated according to the Matthew criteria: good results were obtained in 13 patients, and good results were obtained in 3 of 5 patients. Poor results were seen in two patients. Postoperative X-rays and CT scans showed that 20 patients preserved the joint and 3 patients failed to preserve the joint. After measuring the quality of reduction, joint distance was calculated from functional x-rays. Anatomical reduction (without joint digits) was achieved in 19 patients, while joint digits were detected in 4 patients. The mean step distance was 0.80 mm and the SD was 1.704 (the postoperative x-ray showed a

minimum step of 0 mm and a maximum step of 7 mm). The majority of cases in this study were allowed to gain weight between 8 and 10 weeks, with a mean of 9.34 weeks and a SD of 1.34, which is significant. In our study, most patients were allowed to return to their full weight within 12–16 weeks after radiographic treatment (mean 14.25 weeks, SD 1.8), which is a serious panic. In our study, radiographic healing occurred within 12 to 16 weeks in most patients. The average correction time is 14.24 (SD1.86), which reveals the importance of the data. At the last evaluation, according to the Merle D'Aubigne score, treatment results were evaluated as good in 12 patients (18), good in 5 cases (15–17), fair in 3 cases (13–14), and 3 patients. Complaints. The results were negative. Two patients developed AVN, and one patient developed sciatic nerve palsy, which later recovered. All patients were free from arthritis.

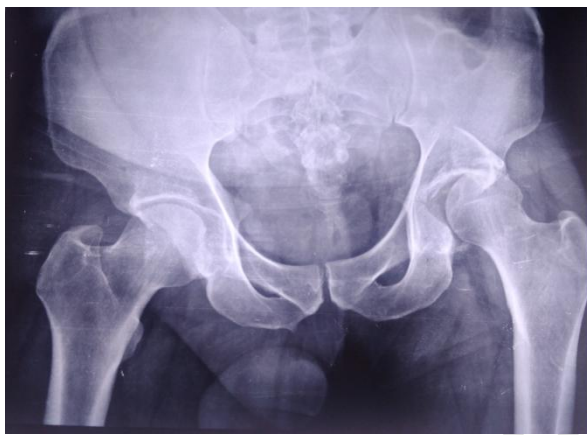

Figure 2 Pre-operative X ray

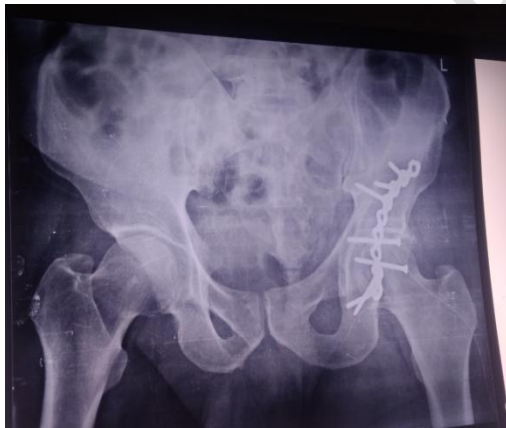

Figure 3 Post-operative x ray

Discussion: - Acetabular fractures are complex, high-energy injuries that can cause serious side effects, regardless of treatment. Major factors include inadequate reduction, osteochondral defects in the acetabulum or femur at the time of injury, osteoarthritis, AVN of the femoral head, Heterotopic ossification, sciatic nerve damage, and infection¹¹. Although the incidence of the disease has decreased due to modern operating rooms and aseptic practices, it remains prevalent in developing countries, which can lead to more antibiotics and longer hospital stays. repeated

debridement, change of infected implant, prolong rehabilitation, morbidity, and death. Bone fracture pattern, small impacts, and more than 2 mm displacement are known to be associated with the development of arthritis. According to statistics from local hospitals in India, after surgical repair of acetabular fractures, 74.6% of patients using the ilioinguinal approach achieved good results or treatment comparable to the results of international studies.¹³ The continuous iliofemoral or tri-radiate approach carries the greatest risk of Heterotopic ossification (excessive bone formation), whereas the ilioinguinal approach has the least Risk of ossification. A higher incidence has been reported in series using extension¹⁵. Over the past 40 years, the treatment of acetabular fractures has shifted from conservative treatment to active treatment. A meta-analysis was performed to evaluate the incidence, distribution, and functional outcomes of complications in patients who underwent surgical treatment for such injuries. no, where the authors analyzed a total of 3 670 bones from the surgically repaired acetabulum. A meta-analysis showed that the overall incidence of post-traumatic nerve palsy associated with acetabular fractures was 16.4%, compared to the findings of Letournel and Judet¹⁶. The overall incidence of wound infection was recorded at 4.4%. The incidence of avascular necrosis (AVN) of the femoral head was recorded in 18 studies involving 2010 patients, with an overall incidence of 5.6%¹⁷. 25 patients were included in our study, and most of our patients were male. This is because most fractures occur from peak trauma (RTA), so men will be injured more in our environment¹⁸. Other major orthopedic surgeries and other international acetabular surgeries with fractures Prevention of infection and strict wound management in the early stages of a suspected infection are unclear. Emerging diseases can be unpredictable and have negative consequences. Cases are often indeterminate and may be related to initial trauma, soft tissue augmentation, lymphatic damage, or bone damage from surgery. However, patient selection, antibiotic prophylaxis, and appropriate surgical treatment can help reduce the disease Surgery can be postponed until surgery Fever and leukocytosis can be evaluated and treated. Second- or third-generation cephalosporin's are routinely used during and for at least 48 hours after surgery, and drainage tubes are placed in each crypt of the wound. In the current series, postoperative sciatic nerve injury occurred in 10 patients, or 13.3%, without somatosensory monitoring. Sciatic nerve damage may result from traction on the sciatic nerve during surgery. There are many typing machines used by many authors to evaluate the outcome of surgery involving the hip area, many of which report positive results. However, it is believed that these hip tests are designed to evaluate total hip replacement and are not good for patients with acetabular fractures. Surgical complications were compared with other major orthopedic surgeries and other international acetabular fracture series. Prevention of infection and strict wound management in the early stages of suspected infection are unclear. Emerging diseases can be unpredictable and have negative consequences. Cases are often indeterminate and may be related to initial trauma, soft tissue augmentation, lymphatic and bone damage from surgery. However, patient selection, antibiotic prophylaxis and appropriate surgical treatment can help reduce the disease Surgery can be postponed until surgery Fever and leukocytosis can be evaluated and treated. Second or third generation cephalosporin's should be administered daily during and for 48 hours after surgery and a drain should be placed in each wound. Incidence of heterotopic ossification in this study Ossification was observed in 3 (4%) patients after three months of follow-up. Heterotrophic ossification is a common problem in acetabular injuries. The formation of large heterotrophic

bones occurs unpredictably¹⁹. Theories attempted to explain the formation of ectopic bones include more than just removal of the hip musculature from the external iliac fossa, more surgery, larger patients, and greater exposure. extension method (not used in our series). Methods to prevent heterotrophic ossification were not used in this series, but various methods such as bisphosphonates, indomethacin and application of low radiation have been described in the literature^{20, 21} Therefore, a "new acetabular fracture scoring system" has been proposed as a better method for reporting acetabular fracture results. The frequency of acetabular fractures is also increasing due to the increase in car accidents. Since these bones connect to the heavy joints of the lower leg, they need to be repaired as much as possible, and this reduction can only be achieved with open surgery and the correct method. Patients with complex acetabular fractures in India should be referred to specialist centers where the best surgeons understand the complexity of these fractures as experience is important. Stable Reduction and anatomical reduction lead to fewer hospitalizations and better clinical outcomes.

CONCLUSION: -Acetabular fractures are orthopedic injuries that require careful attention for correct operation. It most often occurs in young people after a serious injury. In the early days, the acetabular fracture was managed conservative due to poor understanding of the anatomy and bone structure and the lack of the best technique and surgical procedures, resulting in poor results and serious complication. However, with the advancement of CT scans and 3D reconstructions, fracture patterns have become more common. With advances in surgical techniques and management, treatment of these fractures has become standardized with good results. The surgeon needs to understand the area well. Proper pre-planning, meticulous work and careful study later produce great results. When we analyzed the results of this study, we concluded that open reduction and internal fixation are the preferred treatment. Anatomical reduction with stable fixation as early as possible is the immediate goal of surgical treatment. The limitations of our study is lessor number of cases and shorter follow up periods.

Conflict of interest: - There are no conflicts of interest listed by the authors.

Ethical Approval:

As per international standard or university standard written ethical approval has been collected and preserved by the author(s).

Consent

As per international standard or university standard, patient(s) written consent has been collected and preserved by the author(s).

REFERENCES

1. Anizar-Faizi A, Hisam A, Sudhagar KP, Moganadass M, Suresh C. Outcome of surgical treatment for displaced acetabular fractures. *Malays Orthop J* 2014; 8(3): 1-6.
2. Porter SE, Schroeder AC, Dzugan SS, Graves ML, Zhang L, Russell GV. Acetabular fracture patterns and their associated injuries. *J Orthop Trauma* 2008; 22(3): 165-70.
3. Milenkovic S, Saveski J, Radenkovic M, Vidic G, Trajkovska N. Surgical treatment of displaced acetabular fractures. *Srp Arh Celok Lek* 2011; 139(7-8): 496-500.
4. Mears DC, Velyvis JH, Chang C-P. Displaced acetabular fractures managed operatively: indicators of outcome. *Clin Orthop*. 2003 Feb;(407):173-86.
5. Sathappan S, Qi C, Pillai A. Surgical Stabilization of Pelvic and Acetabular Fractures: A Review on the Determinants of Clinical Outcomes. *Malays Orthop J*. 2010 Mar;4(1):12-8.
6. O'Sullivan REM, White TO, Keating JF. Major pelvic fractures: identification of patients at high risk. *J Bone Joint Surg Br*. 2005 Apr;87(4):530-3.
7. Giannoudis PV, Nikolaou VS. Surgical techniques—How do I do it? *Injury*. 2008 Oct;39(10):1113-8.
8. Letournel E, Judet R, Elson RA. *Fractures of the Acetabulum*. Berlin, Heidelberg: Springer Berlin Heidelberg; 1993.
9. Rockwood and Green's Fractures in Adults: Rockwood, Green, and Wilkins' Fracture [Internet]. eBay. [cited 2013 Nov 18]. Available from: <http://www.ebay.com/itm/Rockwood-and-Greens-Fractures-in-Adults-Rockwood-Green-and-Wilkins-Fracture-/331062187478>
10. Harley JD, Mack LA, Winkquist RA. CT of acetabular fractures: comparison with conventional radiography. *Am J Roentgenol*. 1982;138(3):413-7.
11. Briffa N, Pearce R, Hill AM, Bircher M. Outcomes of acetabular fracture fixation with ten years' follow-up. *J Bone Joint Surg Br* 2011; 93(2): 229-36.
12. Hickok NJ, Shapiro IM. Immobilized antibiotics to prevent orthopedic implant infections. *Adv Drug Deliv Rev* 2012; 64(12): 1165-76.
13. Gupta RK, Singh H, Dev B, Kansay R, Gupta P, Garg S. Results of operative treatment of acetabular fractures from the Third World—how local factors affect the outcome. *Int Orthop* 2009; 33(2): 347- 52.
14. Blokhuis TJ, Frolke JP. Is radiation superior to indomethacin to prevent heterotopic ossification in acetabular fractures: a systematic review. *Clin Orthop Relat Res* 2009; 467(2): 526-30.
15. Haidukewych GJ, Scaduto J, Herscovici D Jr, Sanders RW, DiPasquale T. Iatrogenic nerve injury in acetabular fracture surgery: a comparison of monitored and unmonitored procedures. *J Orthop Trauma* 2002; 16(5): 297-301.

16. Giannoudis PV, Grotz MR, Papakostidis C, Dinopoulos H. Operative treatment of displaced fractures of the acetabulum. A metaanalysis. *J Bone Joint Surg Br* 2005; 87(1): 2-9.
17. Khan SH, Ara I, Raza S, Sipra S. Functional outcome of surgery in patients with acetabular fractures. *J Ayub Med Coll Abbottabad* 2013; 25(1–2): 60-3.
18. Firoozabadi R, O'Mara TJ, Swenson A, Agel J, Beck JD, Routt M. Risk factors for the development of heterotopic ossification after acetabular fracture fixation. *Clin Orthop Relat Res* 2014; 472(11): 3383-8.
19. Popovic M, Agarwal A, Zhang L, Yip C, Kreder HJ, Nousiainen MT, et al. Radiotherapy for the prophylaxis of heterotopic ossification: a systematic review and meta-analysis of published data. *Radiother Oncol* 2014; 113(1): 10-7.
20. Nauth A, Giles E, Potter BK, Nesti LJ, O'Brien FP, Bosse MJ, et al. Heterotopic ossification in orthopaedic trauma. *J Orthop Trauma* 2012; 26(12): 684-8.
21. Dunbar RP Jr, Gardner MJ, Cunningham B, Routt ML Jr. Sciatic nerve entrapment in associated both-column acetabular fractures: a report of 2 cases and review of the literature. *J Orthop Trauma* 2009; 23(1): 80-3.